

From “cage to independence”: good outcomes of an unstable (burst) lumbar fracture, surgically managed with an expandable titanium vertebral cage implant, with posterior transpedicular instrumentation, and rehabilitation program – case presentation

ANGHELESCU Aurelian^{1,2}, CÎMPEANU Cristina³, BĂJENARU Alina Oana³, FRECEA Ionut Octavian³, CHECIU Gheorghe⁴, ONOSE Gelu^{1,2}

Corresponding author: Angheliescu Aurelian aurelian_anghelescu@yahoo.co.uk,

1. Neurorehabilitation Clinic, Teaching Emergency Hospital "Bagdasar-Arseni", Bucharest, Romania
2. "Carol Davila" University of Medicine and Pharmacy, Bucharest, Romania
3. Medical Resident, Neurorehabilitation Clinic, Teaching Emergency Hospital "Bagdasar-Arseni" Bucharest, Romania
4. Spinal Neurosurgical department, Teaching Emergency Hospital "Bagdasar-Arseni", Bucharest, Romania

Abstract

Introduction: The thoracolumbar junction (T11-L2) is biomechanically prone to spinal cord injuries (SCI), as it marks the transition from the rigid thoracic segment to the flexible lumbar spine. The damage of the spinal cord is due to a high-energy trauma (mainly motor vehicle accidents, falls from height, etc), in most cases resulting burst fractures of the lumbar region. The vertebral body is crushed in all directions, retro pulsed bony fragments are spread out towards the spinal canal, damaging the spinal cord, and causing neurologic injuries.

Case report: This is a retrospective case study of a slim 43-year-old woman who suffered on 23.06.2018 a polytrauma (accidental fall from 3m height, from tree), associating thoraco-abdominal contusions, without cranial trauma and a severe L1 vertebral comminuted / burst fracture, followed by flaccid T12 AIS-A (complete) paraplegia.

She underwent a complex neurosurgical approach, with a self-expandable metallic cage (Stryker) and posterior transpedicular stabilization for decompression and circumferential fusion in one stage, without cavity involvement.

In an early post-acute stage she was admitted to the Rehabilitation Clinic (from 10.07.2018 until 31.08.2018) as a T12 AIS-C paraplegia (incomplete neurological lesion, with a global motor score 59/100; lower legs motor score 9/50 [4/25 R+5/25 L], with neurogenic bowel and bladder. The evolution was favorable and she was discharged as L2 AIS-D paraplegia (global motor score 70/100; lower legs motor score 20/50 [10/25 R+10/25 L]).

Discussion: This case report emphasizes the benefits and functional outcomes after a comprehensive therapeutic approach, of a patient with unstable (burst) lumbar fracture, surgically managed with an expandable titanium vertebral cage implant with posterior transpedicular instrumentation, followed by a complex rehabilitation program,

Stryker distractible vertebral body replacement implant is an expandable device, which can adapt to the patient's anatomy, enabling the neurosurgeons to treat severe burst fractures. Rehabilitation objectives were focused on B-ADL independence (activity, component of the ICF-DH framework) – transfers, orthostatic posture, restore walking, bladder control. The vital prognosis and functional outcome were favorable. Although she was able to use a walking frame at discharge, there were a few drawbacks in what concerns the professional reintegration, due to specific external barriers (she was a military personnel, had neither driving license, nor an adapted car).

Conclusions: This clinical case underlines the importance of a complex and multidisciplinary approach, prompt surgical intervention and rehabilitation during the early post-acute phase.

Key words: lumbar burst fractures, paraplegia, vertebrectomy reconstruction, titanium expandable cage, rehabilitation, outcomes,

Introduction

Spinal cord injury (SCI) represents the damage of the spinal cord, mainly caused by traumatic events (such as car crashes, or falls from heights), but it can also have a tumoral, inflammatory, or degenerative etiology. Incidence is 40-80 per million inhabitants, and around 90% of them are due to traumatic causes. Every year, are reported between 250.000-500.000 cases of spinal cord injuries [1].

Spinal fractures are usually the result of a high-energy trauma. The thoracolumbar junction (T11-L2) is biomechanically prone to injury as it marks the transition from the rigid thoracic spine to the flexible lumbar spine [2].

The most common mechanism incriminated for (SCI) is represented by motor vehicle accidents (36.7% of fractures), followed by falls from height (which accounted for 31.7%) [1], [2]. In an american level 1 trauma center, the rate of injury to the thoracolumbar spine was 6.9% [2]. Burst fractures are the ones with the highest incidence [3],[4].

A burst fracture describes a spinal injury in which the vertebral body is severely compressed. Due to the great deal of vertically force applied to the spine, a vertebral body being crushed in all directions, the retro pulsed bony fragments are spread out into the spinal canal and can damage the spinal cord, causing paralysis or partial neurologic injury.

Case report

This is a retrospective case study of a 43-year-old woman who suffered on 23.06.2018 a polytrauma (accidental fall from 3m height - tree), associating thoraco-abdominal contusions, without cranial trauma and a severe L1 vertebral comminuted fracture, followed by flaccid T12 AIS-A (complete) paraplegia. The polytrauma Injury Severity Score (ISS) was 9 out of a possible 75 points [5].

The patient was an active military staff, in good health before the traumatic event, without any comorbidities and she was not taking any medication at home. Her legal family frame was compromised; she was divorced and mother of two young girls (16 and 21 y.o.).

The patient was admitted on 24.06.2018 in the neurosurgery department, and had surgery on 03.07.2018. The surgical treatment consisted in: posterolateral L1 transpedicular approach on the right side, complete L1 laminectomy, L1 pediclectomy, T12-L1 and L1-L2 artrectomy, T12-L1 discectomy, L1 vertebral reconstruction with an expandable metallic cage, and bilaterally posterior rods and transpedicular screw fixation at T11, T12, L2, L3 levels.

There were no post surgery complications, neither hardware displacement, nor surgical site infections.

She was admitted to the Rehabilitation Clinic from 10.07.2018 until 31.08.2018 as a T12 AIS-C (incomplete paraplegia), with neurogenic bowel and bladder.

Neurological status classified according to the American Spinal Injury Association (ASIA) impairment scale, and functional outcomes are presented in fig 1.

The patient had stable vital signs: respiratory rate – 18/min, heart rate – 84/min, blood pressure – 115/80 mmHg, indwelling urinary catheter, no pressure sores.

Complete blood count and biochemical laboratory tests (before surgery and in the rehabilitation clinic) were within normal parameters .

Fig. 2 – 5 illustrate pre- and postsurgical imagery.

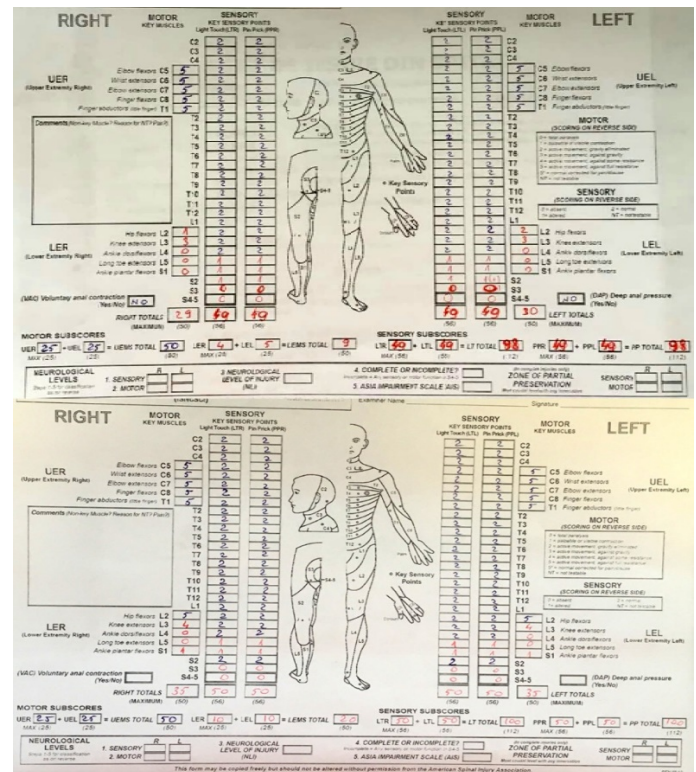


Fig 1. ASIA evaluation at admission (up): T12 AIS-C paraplegia (global motor score 59/100; lower limbs (LL) motor score 9/50 [4/25 R+ 5/25 L], pinprick score 98/112, light touch score 98/112, saddle anesthesia). ASIA evaluation at discharge (down): L2 AIS-D paraplegia (global motor score 70/100; LL motor score [10/25 R+ 10/25 L], pinprick score 100/112, light touch score 100/112, saddle anesthesia).

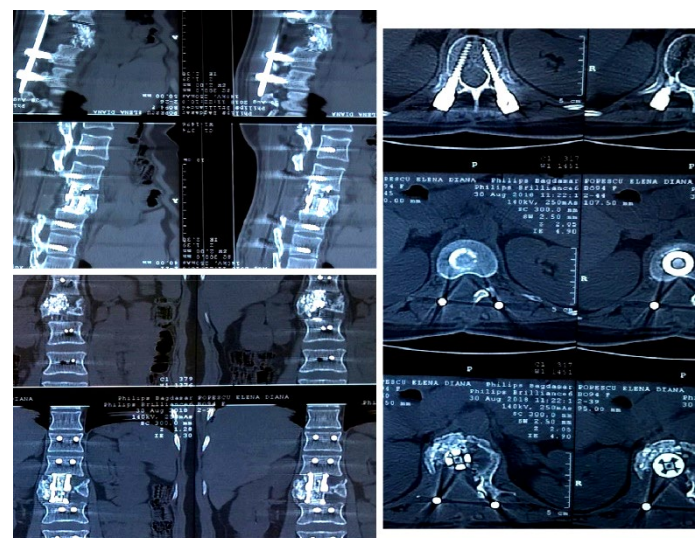


Fig 2. Preoperative computed tomography (CT). Lumbar spine lateral view in a 43 year old woman, showing L1 burst fracture, with multiple bone fragments inside the spinal canal and severely narrowed spinal canal.

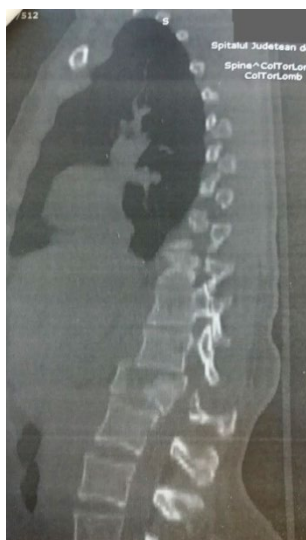

Fig 3. Presurgical MRI T2-weighted images. L1 burst fracture, with multiple bone fragments compressing the spinal cord.

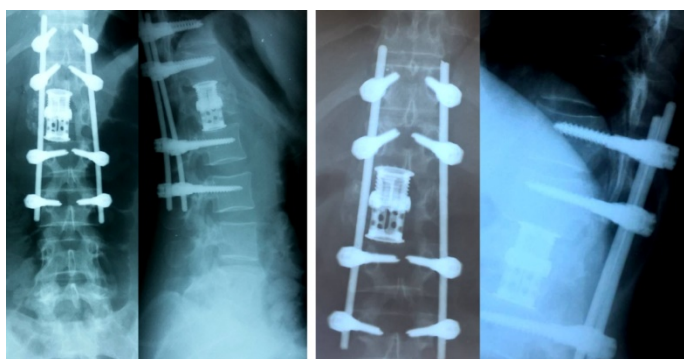


Fig 4. Postsurgical Rx vertebral images in the rehabilitation clinic: at admission (left side images) and discharge (right side images).

Complex system stabilization (metallic vertebroplasty with Stryker expandable cage, and posterior arthrodesis with screws and rods).

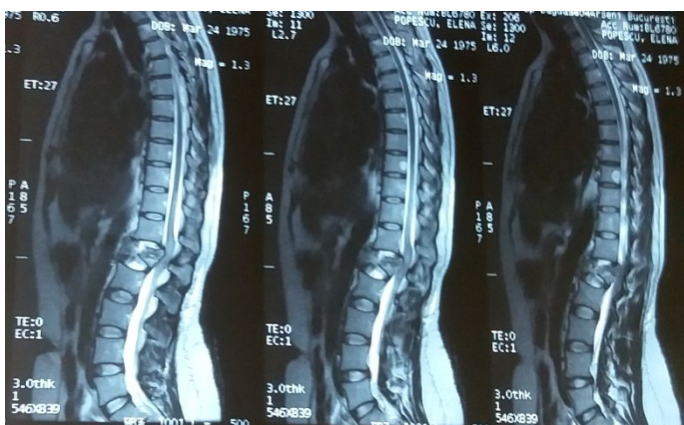

Fig 5. Postoperative CT at discharge (30/08/2018) demonstrated complete removal of the bony fragments from the spinal canal, spine fixation with complex vertebroplasty using Stryker vertebral body replacement system and posterior transpedicular stabilization.

After surgery the patient received prophylactic anticoagulation with subcutaneous nadroparine (fraxiparine 0.6 ml), pain relief medication, and urinary antiseptics to avoid infections, complex synergic association of neurotrophic drugs. After verticalization, anticoagulant was then replaced with antiplatelet medication, also recommended at discharge.

She was confined in bed for 3 weeks then mobilized and she exercised a few steps with the walking frame. Bladder rehabilitation program consisted in intermittent urinary catheterization with pre lubricated sterile probes. The outcome was favorable (fig 1), without additional neurological deficits and stable vital functions.

Discussion

Burst fractures involve the anterior and middle columns with an intact posterior column, so they are biomechanically unstable. These are commonly found in the thoracolumbar junction, which is a considerably high vulnerable region [6]. The most common mechanism of thoracolumbar fractures is high fall injury, and the most commonly injured being L1 vertebra, occurring at a rate of 34.4% (± 15.90) [2], [3].

A systematic review of the literature and meta-analysis (including over 3500 patients) focused on the epidemiology and fracture morphology noticed in thoracolumbar spinal trauma. Burst/AO type A3 were the most common morphological pattern of spinal fractures [39.50% (± 16.30)] [2], [4] followed by compression/AO type A1 [33.60% (± 15.10)], fracture dislocation/AO type C [14.20% (± 8.08)], and flexion distraction/AO type B, with a morphology rate of 6.96% (± 3.50) [4].

A burst vertebral fracture is classified as unstable if angulations of the spine are greater than 20 degrees, generates a vertebral subluxation or dislocation, more than 50% of the spinal canal is compromised by offending bony fragments, important neurological deficits and complications are present at the time of injury.

The main surgical objective our case aimed to provide spinal stabilization and fixation, enough to start physiotherapy and accomplish this goal with less morbidity as possible. The management for unstable T12 and L1 fractures requires early surgical procedures to stabilize the spine. Surgical treatment for lumbar burst fractures include decompression of the neural elements to promote recovery, correction

of spinal deformity, fusion with rigid stabilization, preservation of vertebral motion segments, and prevention of development of delayed deformities [7].

The particularity of this case is represented by the complex and less frequent neurosurgical method (applied in our spinal surgical center), in treating patients with severe vertebral fracture in the lumbar region. Extensive injury of anterior and medial spinal columns required partial or complete removal of the vertebral body (corpectomy). Only selected cases can require corpectomy, due to the possibility to compromise spine stability and sagittal balance.

Stryker distractible vertebral body replacement implant is an expandable titanium cage, which can adapt to the patient's anatomy, enabling the neurosurgeons to treat severe burst fractures. Self-expandable cages and posterior transpedicular stabilization allow decompression, stabilization and circumferential fusion in one stage without cavity involvement [2], [8], [9], [10], [11]. Anterior corpectomy and fixation with an expandable cage, lateral (posterolateral) rod and screws arthrodesis allows vertebral fusion through the same single exposure. It is a safe and effective surgical procedure, with minimal complications [8], [9], [10], [11].

Physical therapy objectives were focused on maintaining joint limb mobility and increasing joint stability, augmentation of the cardio-respiratory endurance, improve global motor control, coordination and equilibrium. Lower limbs level therapy goals were to maintain trophicity in the distal myomers L4-5-S1, increase force, equilibrium and coordination necessary for walk recovery. The aim of physiotherapy at the pelvis and trunk levels was targeted to increase force, equilibrium and stability in walking. Therapy training of the upper limbs aimed to increase force and get sufficient ability to manipulate the walking frame.

Rehability training was focused on B-ADL independence (activity, component of the ICF-DH framework) – transfers, orthostatic posture, restore walking, bladder control. Increase coping and self-esteem represented another important objective to achieve.

Bladder training program consisted in self-catheterization with sterile, pre-lubricated probes and bladder stimulation with interferential medium frequency currents. Its goal aimed to avoid urinary

tract infections (UTI), prevent acute and late renal complications, maintain the person “dry” for social reintegration. Our patient was discharged with a bladder training program and recommendation for urinary probes, provided freely by the National Insurance House [12].

Ad vitam outcome and *ad functionem* prognosis were favorable (fig.1). Somatic improvement targeted enhancement in B-ADL / activity enrichment. Favorable functional outcomes were achieved, locomotor status significantly improved. At discharge she was able to walk with a walking frame and bilateral anti-drop (foot-ankle) orthosis.

Ad laborem outcome was reserved, due to the external barriers in the community, represented by the nature of her job (military personnel), the distance and transport problems (the subject lives in Ilfov district, and she has neither driving licence, nor an adapted car) [13], [14].

Marital status represented also a barrier to the social reinsertion, because our patient is a divorced woman, who must support two teenage daughters. Education is mandatory at discharge: although vaginal and clitoral orgasmic capacities are theoretically abolished, the patient is young enough and might have risk for UTIs and / or sexually transmitted diseases (by vaginal, anal, or oral intercourse). Also pregnancy might be possible (because her menstrual cycle returned).

Social participation and the quality of life were the most important objectives for the rehabilitation endeavours, targeted on our young woman living with SCI. Familial reintegration and socio-professional independence represented the golden targets for rehabilitation.

Prompt surgical intervention and rehabilitation during the early post-acute phase, complex, and comprehensive approach in a multidisciplinary team represented the key elements for the favorable outcome of our reported case.

Abbreviations

SCI, spinal cord injury

B-ADL, basic activities of daily living

ICF-DH, International Classification of Functioning, Disability and Health

UTI, urinary tract infection

Disclosures

The authors have no conflicts of interest to disclose. The paper has the approval of the Bioethics Commission of the Bagdasar Arseni Emergency Clinical Hospital (TEHBA), Bucharest

References

1. Onose Gelu, Angheliescu Aurelian si colab, Rehabilitation in conditions following spinal cord injuries, in *Tratat de Neurochirurgie, Vol. 2* ("Textbook of Neurosurgery"); Editura Medicala 2011 (ISBN 978 - 973-39-0720-6)
2. Wood KB, Li W, Lebl DS, Ploumis A., Management of thoracolumbar spine fractures. *Spine J Off J North Am Spine Soc.* 2014;14(1):145–164. DOI: 10.1016/j.jor.2016.06.019
3. Panteliadis P, Musbahi O, Muthian S, Goyal S, Montgomery AS, Ranganathan A., Comparison of Three Different Methods of Fixation in the Management of Thoracolumbar Fractures. *Int J Spine Surg.* 2018 30;12(1):1-7. doi: 10.14444/5001..
4. Katsuura Y, Osborn JM, Cason GW., The epidemiology of thoracolumbar trauma: A meta-analysis. *J Orthop.* 2016 21;13(4):383-8. doi: 10.1016/j.jor.2016.06.019. eCollection 2016 Dec.
5. Rau, C.-S., Wu, S.-C., Kuo, P.-J., Chen, Y.-C., Chien, P.-C., Hsieh, H.-Y., & Hsieh, C.-H. (2017). Polytrauma Defined by the New Berlin Definition: A Validation Test Based on Propensity-Score Matching Approach. *International Journal of Environmental Research and Public Health*, 14(9), 1045. <http://doi.org/10.3390/ijerph14091045>
6. <https://www.braceability.com/blogs/articles/t12-l1-spinal-thoracic-burst-fracture>
7. Sasagawa T, Kawahara N, Murakami H, Demura S, Tomita K, *Orthopedics.* 2009;32(10). pii: orthosupersite.com/view.asp?rID=43774. doi: 10.3928/01477447-20090818-28.
8. Richardson B, Paulzak A, Rusyniak WG, Martino A., Anterior Lumbar Corpectomy with Expandable Titanium Cage Reconstruction: A Case Series of 42 Patients. *World Neurosurg.* 2017;108:317-324. doi: 10.1016/j.wneu.2017.08.179
9. Huang Z, Ding Z, Liu H, Fang J, Liu H, Sha M. Anterior D-rod and titanium mesh fixation for acute mid-lumbar burst fracture with incomplete neurologic deficits: A prospective study of 56 consecutive patients. *Indian Journal of Orthopaedics.* 2015;49(4):471-477. doi:10.4103/0019-5413.159680
10. Graillon T, Rakotozanany P, Blondel B, Adetchessi T, Dufour H, Fuentes S., Circumferential management of unstable thoracolumbar fractures using an anterior expandable cage, as an alternative to an iliac crest graft, combined with a posterior screw fixation: results of a series of 85 patients. *Neurosurg Focus.* 2014;37(1):E10. doi: 10.3171/2014.5.FOCUS1452.
11. Graillon T, Farah K, Rakotozanany P, Blondel B, Adetchessi T, Dufour H, Fuentes S., Anterior approach with expandable cage implantation in management of unstable thoracolumbar fractures: Results of a series of 93 patients. *Neurochirurgie.* 2016; 62(2):78-85. doi: 10.1016/j.neuchi.2016.01.001
12. Spinu A, Onose G, Daia C, Panțu C, Angheliescu A, Onose L, Mihăescu A. - Intermittent catheterization in the management of post spinal cord injury (SCI) neurogenic bladder using new hydrophilic, with lubrication in close circuit devices--our own preliminary results. *J Med Life.* 2012, 22;5(1):21-8. Epub 2012 Mar 5.
13. Angheliescu Aurelian, Buscă Mihai, Constantin Adina, Andone Ioana, Angheliescu Lucia Ana-Maria, Onose Gelu, Employment of People with Disabilities in Romania, *International Archives of Medicine* (2016) ISSN 1755-7682, DOI: <http://dx.doi.org/10.3823/2236>
14. Angheliescu Aurelian, Integration and (Re-) Employment of People Living with Sequelae Post Spinal Cord Injury—successful Socioeconomic Evolution—from Cinderella, to the Wonder Princess *Int J Neurorehabilitation* (ISSN: 2376-0281) <http://dx.doi.org/10.4172/2376-0281.1000e121>