

Clinical, paraclinical aspects and complex therapeutical approaches in a patient with incomplete paraplegia, post thoracic meningioma surgically treated, in neurofibromatosis context

SPÎNU Aura¹, ANDONE Ioana^{1,2}, CHIPĂRUȘ Carmen¹, FRUNZA Andreea¹, STOICA Simona^{1,2},
ONOSE Liliana³, PATRAȘCU George¹, ONOSE Gelu^{1,2}

Corresponding author: **Ioana Andone**, E-mail: ioanaandone11@yahoo.com

1. Teaching Emergency Hospital "Bagdasar-Arseni" (TEHBA), Bucharest, Romania
2. University of Medicine and Pharmacy "Carol Davila" (UMPCD), Bucharest, Romania
3. The Medical Service of Metrorex SA, Bucharest, Romania

Abstract

Introduction: Neurofibromatosis - type 1 (NF1) and type 2 (NF2) - are genetic disorders of the nervous system that can affect the growth and development of nerve cell tissue and so can determine severe or rather permanent sequels. NF2 implies usually multiple tumors on the cranial and spinal nerves and it is less common than NF1. The most frequent symptom of NF2 is hearing progressive loss, as a consequence of auditory nerves affection and appears at early ages or at twenties. The evolution of a patient with NF2 depends on the number and location of tumors and some of them might develop a life-threatening or disabling condition. With a prompt diagnosis and an appropriate therapy it can be improved the patient prognosis and QOL.

Materials and Methods: This paper presents the case of a 43-year-old patient, with personal antecedents of hearing dysfunction, diagnosed in 2013 with neurofibromatosis that was hospitalized at the IV Neurosurgery Clinic of TEHBA in January 2019 and suffered a re-intervention for removal of the spinal cord tumor (psammomatous meningioma) and with spinal cord decompression. In our clinic, the patient was admitted for incomplete AIS/Frankel C paraplegia, he had initially followed a complex nursing program and subsequently a rehabilitation adequate program. The patient was assessed functionally using the following scales: AIS / Frankel, modified Ashworth, Functional Independence Measure (FIM), Life Quality Assessment (QOL), FAC International Scale, Independence Assessment Scale in Daily Activities (ADL / IADL), Walking Scale for Spinal Cord Injury (WISCI).

Results: The paraclinical assessments (cerebral and spinal cord MRI) detect multiple cerebral tumors and micro-nodules adjacent to the lumbar spinal roots, which, associated with the bilateral acoustic neurinoma (diagnosed in 2013), contributed to the suspicion of the NF2 diagnosis. The patient had two admissions in our clinic division, benefited from a complex neuro-muscular rehabilitation program, having a favourable evolution, with an increase in the evaluated scales scores, now performing walking with a support from another person in walking frame, as well as sphincter re-education, with the neurogenic bladder remission.

Conclusions: Even if there is no cure for neurofibromatosis and no standard treatment, it is important to promptly diagnose such a rare disease and to give an adequate treatment (AINS or other analgesic drugs, surgery, chemotherapy or radiation –when it's needed, or psychotherapy) for controlling symptoms and also a personalized rehabilitation program (including nursing measures) enhancing including patient's quality of life.

Key words: *paraplegia, neurofibromatosis, neuro-muscular rehabilitation,*

Introduction

Neurofibromatosis - type 1 (NF-1) and type 2 (NF-2) - are genetic disorders of the nervous system that can affect the growth and development of nerve cell tissue and so can determine severe or rather permanent sequels.

Neurofibromatosis type1, also called von Recklinghausen's disease, is the most common one (90% of all cases) (1) has an incidence by 1 in 3000 people (2) and it is an autosomal dominant disease affecting the skin, nervous system and bones. NF-1 it is caused by the mutation of a gene (that regulates production of neurofibromin protein – a tumor

suppressor) on the chromosome 17 and in 50% of cases this mutation it is done spontaneously. (2)

Diagnosis of NF-1 is made by matching at least 2 of the following 7 diagnostic criteria:

- six or more café au- lait spots
- two or more neurofibromas
- axillary and/or inguinal freckles
- optic glioma
- two or more Lisch nodules
- specific long bones abnormalities or sphenoid dysplasia
- first degree relatives with NF1(3)

Neurofibromatosis type II is also known as MISME syndrome – multiple inherited schwannomas, meningiomas, and ependymomas. (4) Being a genetic condition, it may be inherited or may arise spontaneously.

NF-2 implies usually multiple tumours on the nervous system and it is less common than NF-1 (incidence of 1 in 60,000). (4)

NF-2 is caused by mutations of the "Merlin" (Moesin-ezrin-radixin-like protein) gene (5) which is a tumour suppressor protein, located on chromosome 22q. At the beginning, Merlin was described to be a structural protein with the function of an actin cytoskeleton regulator and later on, its tumor suppressant role was discovered.

Pathogenesis

In people with NF-2 and ependymomas, the tumor suppressant function of Merlin may be compromised. Tumorigenesis are determined by the loss of function mutations in chromosome 22q, the place Merlin proteins are coded. (6)

Clinical manifestations of this disease, includes symptoms generated by the potential tumors that can appear, such as: brain or spinal cord tumors, peripheral nerve tumors.

Symptoms of Brain Tumors:

- Loss of hearing
- Facial drop
- Dizziness, headaches
 - Poor balance - uncoordinated walking/ vertigo, unsteady gait
 - Speech difficulties
 - Dysphagia (Swallowing Issues – choking, coughing while eating or drinking)

Vision Issues:

- Intracranial and Intraorbital Tumors
- Cataracts (cloudy areas on the lens of the eye) that develop at an unusually early age
- Diplopia (Double Vision)
- Dry Eye (Inability to produce tears)
- Oscillopsia (Fuzzy Vision)
- Papilledema (Swelling of Optic Nerve)

Symptoms of spinal cord tumors (schwannomas; meningiomas; ependymomas; astrocytomas):

- Drop Foot
- Scoliosis
- Tingling/Numbness of Limbs
- Back pain from the enlarging of the spine tumors,
- Weakness in the fingers and toes

Symptoms of Peripheral Nerve Tumors (brachial plexus tumors - upper arm/neck); sciatica nerve tumors - lower back/hip/upper leg; tibia nerve tumors - lower leg; median nerve tumors –arm):

- Hand / drop foot
- Peripheral neuropathy
- Muscle weakness
- Tingling/ numbness of limbs
- Pain

Individuals with NF-2 usually develop symptoms during early adulthood. Affected people generally have fewer brown macules on the skin than those having NF1 type (8). The most frequent symptom of NF-2 is hearing progressive loss, as a consequence of auditory nerves affection (7) (the hallmark lesions of NF-2 are bilateral acoustic Schwannomas, which affect almost all patients) and appears at early ages or at twenties. Besides, about a half of patients will develop tumours in other cranial nerves or the meninges, and also spinal tumours occur (7). The evolution of a individual depends on the number and location of tumours and it is to be mentioned that some of them might develop a life-threatening potential. It is important a prompt diagnosis in order to apply an appropriate therapy. (7)

Current and revised Manchester criteria for NF-2 (9)

1. Bilateral vestibular schwannomas (VS) <70^a or
 2. First degree relative (FDR) family history of NF2 and unilateral vestibular schwannoma (UVS) < 70^a or
 3. FDR family history of NF-2 or UVS and 2 of ^b meningioma, cataract, glioma, neurofibroma, schwannoma, cerebral calcification or
 4. Multiple meningiomas (2 or more) and 2 of unilateral VS, cataract, glioma, neurofibroma schwannoma, cerebral calcification or
 5. Constitutional or mosaic pathogenic NF-2 gene mutation in blood or identical mutations in 2 distinct tumors ^a
- a: 2016 suggested revisions.
b: any 2 includes 2 of any tumor type such as schwannoma.

Diagnosis (10)

Neurofibromatosis is diagnosed using following tests:

- Physical examination
- Medical history
- Family history

- X-rays
- Computerized tomography (CT) scans
- Magnetic resonance imaging (MRI)
- Biopsy of neurofibromas
- Eye tests
- Audiometry
- Genetic testing (can demonstrate the presence of a mutation on the NF-1 or NF-2 gene)

Treatment

Neurofibromatosis cannot be cured but treatments are focused on controlling symptoms. Many symptoms, such as café au lait spots, do not need treatment. Though, we have to underline some options of treatment:

- Surgery in case of growing tumors
- Chemotherapy or radiation if a tumor has turned malignant
- Orthopedic surgery for postural spine problems, like scoliosis
- Physical therapy
- Cataract removal surgery
- AIS/AINS treatment of associated pain/symptoms

Surgical treatment

There are several different surgical techniques for the removal of acoustic neuroma (retro-sigmoid approach, trans-labyrinthine approach, middle fossa approach).(11) The choice of the operation depends on the size of the tumor, the hearing impairment and general health. Unfortunately, the chance of hearing preservation is small in large tumors, no matter the procedure chosen. When hearing is impaired, the trans-labyrinthine approach may be used for small tumors. In case of small, lateralized tumors with good hearing it is recommended the middle fossa approach. When the location of the tumor is more medial, a retro-sigmoid approach may be better.

Radiosurgery - types include also a lot of technics: SRS (stereotactic radiosurgery), Gamma Knife, CyberKnife, Proton Therapy which is a conservative alternative focused on the tumour sparing exposure to surrounding normal tissues. The goal of radiation therapy is to prevent the tumor growth. Although radiation is less immediately damaging than conventional surgery, it incurs a higher risk of subsequent malignant change in the irradiated tissues.

It is to be noticed that there is a significant risk of hearing loss with surgical removal of acoustic neuroma. (12)

Hearing Loss

People with NF-2 hearing problems (including deafness) are more likely to resort to auditory assistive technology such as the cochlear implant which can be used as a device for restoring a high level of auditory function even when natural hearing is totally lost.

An auditory brainstem implant may be another option when the cochlear nerve is destroyed, in order to restore some level of hearing, supplemented by lip reading (13)

Hearing may be preserved if diagnosed in time, but if not, patients may require an auditory assistive device, as mentioned above. (14)

Prognosis

The long-term prognosis for people with NF-2 depends on a number of factors, as the age onset and the number and location of tumors as they can vary significantly from person to person. The tumors associated with NF-2 are mostly benign, but they can reduce significantly the quality of life of these patients.

The average age of death in people with NF-2 is 36 years and earlier diagnosis followed by the proper treatment in specialty centers may improve life expectancy with more than 15 years. (15, 16,17)

Case Presentation

This paper presents (with the approval of the Bioethics Commission no.17464/14.06.2019) the case of a 43 year-old patient, with personal antecedents of hearing dysfunction and phonation disorders, diagnosed in 2013 with neurofibromatosis (he accused some headache and tinnitus for two years before the NF confirmation and he went to many doctors until an ORL doctor recommended him a brain MRI – that revealed the multiple expansive intracranial processes).

In 2018, he begun to develop subjective severe thoracic-lumbar pain and neurologic deficit on lower limbs and he was hospitalized at Emergency Hospital Floreasca, where following investigations, a tumoral mass at T10 level was identified.

The first exploratory intervention – considering the risk of a vascular malformation - on the spinal cord lesion, at T7-T10 level, has been done on December 2018, at the hospital above mentioned.

Next, because he was still having thoracic pain and neurologic impairment, he was hospitalized at the IV Neurosurgery Clinic of TEHBA in January 2019 where he was subjected to a re-intervention for the removal of the spinal cord tumor, with a spinal cord decompression.

The anatomo-pathological examination revealed at a macroscopic analysis multifragmentary piece of 3,5 /2/ 1,5 cm, grey color, with elastic consistency and the microscopic analysis pointed out a psammomatous meningioma from NF-2.

After an insidious evolution, the patient was admitted in TEHBA Neuro-Muscular Clinic Devision 25.01-21.03.2019. In our clinic, the patient initially followed a complex nursing program and subsequently a rehabilitation adequate program.

The onset of the patient's symptoms: motor deficit in lower limb, sphincter's impairment, phonation disorders and moderate deficit of locomotion/ selfcare.

Physical examination: he was underweight, afebrile, with a satisfactory general appearance. The blood pressure was 110/70 mmHg, pulse 98/min, oxygen saturation was 98% spontaneously, irradiated systolic blow on carotids, pale teguments with a post-operative plague at thoracic level, important muscular hypotrophy (lower limbs more than upper limbs). He had a persistent neurogenic bladder dysfunction – using a fixed urinary catheterization- and also, of neurogenic bowel – including constipation.

The patient presented 6 pigmentary café au-lait macules on the anterior thorax that spotted around the age of 20 years old with only 2 of them having more than 15 mm in diameter.

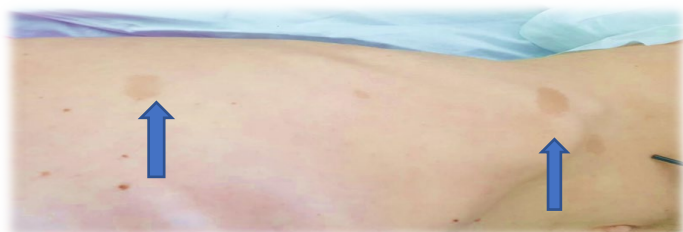

Fig. 1: Pigmentary café au-lait macules on the patient's anterior thorax (from TEHBA Neuro- Rehabilitation Clinic Devision).

Neurofibromas with small dimensions, less than 4 cm in diameter (soft, fleshy growths under the skin) situated on the left forearm, on the left ear, right hand that appeared for 4 years.

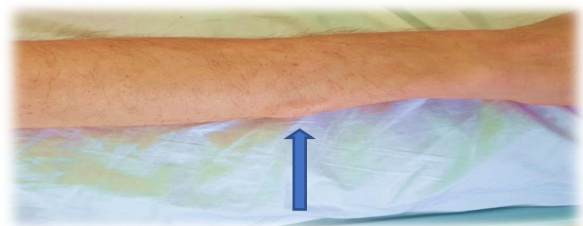


Fig. 2: Neurofibromas on the patient's forearm (from TEHBA Neuro-Rehabilitation Clinic Devision).

Neurological examination showed a temporo-spatial oriented, conscious and cooperative person, with important dysphonia (right vocal cord paralysis when he was 20 years old), injury on cranial nerve X bilateral hearing loss (left> right), injury on cranial nerve VIII, motor deficit (according to AIS/Frankel Scale- AIS/Frankel C) of paraplegia type, with T8 neurological level.

Initially the osteotendinous reflexes were decreased and after one month he had bilateral Babinsky reflex.

The patient was assessed functionally using the following scales:

- AIS/Frankel (American Spinal Injury Association Impairment Scale): 74 motor from 100 points, sensory 204 from 224 points

- Ashworth Modified Scale: Spasticity = 2 on left leg

- FIM (Functional Independence Measure): motor 45 points; cognitiv 35 points

- QoL (Life Quality Assessment Quality of Life): 57 points,

- Walking Scale for Spinal Cord Injury (WISCI): 0 points

- Functional Ambulation Categories (FAC) International Scale: 0

From the functional point of view, the patient was immobilized in bed.

Patient Name _____ Examiner Name _____ Date/Time of Exam _____

ASIA STANDARD NEUROLOGICAL CLASSIFICATION OF SPINAL CORD INJURY **ISC**

MOTOR KEY MUSCLES (scoring on one side)

	R	L
C5		
C6		
C7		
C8		
T1		
TOTAL (MAXIMUM)	(20)	(20)

UPPER LIMB TOTAL (MAXIMUM) (20) (20) (40)

SENSORY KEY SENSORY POINTS

	R	L
C2		
C3		
C4		
C5		
C6		
C7		
C8		
T1		
T2		
T3		
T4		
T5		
T6		
T7		
T8		
T9		
T10		
T11		
T12		
L1		
L2		
L3		
L4		
L5		
S1		
S2		
S3		
S4-S5		
TOTALS (MAXIMUM)	(28)	(28)

LOWER LIMB TOTAL (MAXIMUM) (28) (28) (56)

NEUROLOGICAL LEVEL (The first level segment with normal function)

COMPLETE OR INCOMPLETE? (Impairment in sensory or motor function in S4-S5)

ASIA IMPAIRMENT SCALE

ZONE OF PARTIAL PRESERVATION (Caudal extent of sensory/motor impairment)

KEY SENSORY POINTS

Any anal sensation (Yes/No) ☐ Yes ☐ No

PIN PRICK SCORE (max: 112)

LIGHT TOUCH SCORE (max: 112)

ASIA IMPAIRMENT SCALE

NEUROLOGICAL LEVEL (The first level segment with normal function)

COMPLETE OR INCOMPLETE? (Impairment in sensory or motor function in S4-S5)

ASIA IMPAIRMENT SCALE

ZONE OF PARTIAL PRESERVATION (Caudal extent of sensory/motor impairment)

KEY SENSORY POINTS

Any anal sensation (Yes/No) ☐ Yes ☐ No

PIN PRICK SCORE (max: 112)

LIGHT TOUCH SCORE (max: 112)

ASIA IMPAIRMENT SCALE

Fig. 3: American Spinal Injury Association (ASIA) Impairment Scale (AIS) scoring (after: <http://www.scribd.com/doc/37064936/2006-Classif-Worksheet>) – with included/ adapted Frankel's grading semi-quantitative system – to describe/ assess the severity of cord lesion's consequent (neurologic and functional) impairment – with some main related clinical syndromes

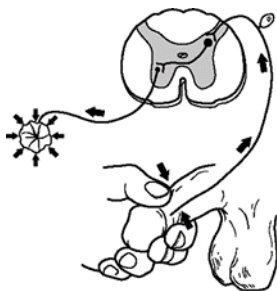

Fig. 4: Bulbo- cavernous reflex (with permission, by elearnSCI.org Submodule: Clinical assessment of patients with SCI - Doctor's Module - Aito S (Coordinator) et al., 2012 - <http://www.elearnsci.org/>









































FIM™ instrument					
LEVELS	7	Complete Independence (Timely, Safely)	NO HELPER		
	6	Modified Independence (Device)			
	Modified Dependence		HELPER		
	5	Supervision (Subject = 100%+)			
	4	Minimal Assist (Subject = 75%+)			
	3	Moderate Assist (Subject = 50%+)			
	Complete Dependence				
	2	Maximal Assist (Subject = 25%+)			
	1	Total Assist (Subject = less than 25%)			
Self-Care		ADMISSION	DISCHARGE	FOLLOW-UP	
A.	Eating				
B.	Grooming				
C.	Bathing				
D.	Dressing - Upper Body				
E.	Dressing - Lower Body				
F.	Toileting				
Sphincter Control					
G.	Bladder Management				
H.	Bowel Management				
Transfers					
I.	Bed, Chair, Wheelchair				
J.	Toilet				
K.	Tub, Shower				
Locomotion					
L.	Walk/Wheelchair				
M.	Stairs				
Motor Subtotal Score					
Communication					
N.	Comprehension				
O.	Expression				
Social Cognition					
P.	Social Interaction				
Q.	Problem Solving				
R.	Memory				
Cognitive Subtotal Score					
TOTAL FIM Score					

Fig. 5: Endorsed by the USA Department of Veterans Affairs, since 2003 Guide for the Uniform Data Set for Medical Rehabilitation, Version 5.1 Buffalo, State University of New York at Buffalo - from Uniform Data System for Medical Rehabilitation, UBFA – cited in Braddom R. L. et al. – Physical Medicine & Rehabilitation (3rd edition). W. B. Saunders Company, Philadelphia, USA., 2007

Nr.	Categorie	Caracterizare
0	Nefuncționalitate	Pacientul nu poate merge sau necesită ajutor de la 2 sau mai multe persoane
1	Dependență - nivel 2	Pacientul necesită sprijin ferm și continuu din partea unei persoane
2	Dependență - nivel 1	Pacientul necesită sprijin continuu sau intermitent din partea unei persoane pentru ajutor cu echilibrul sau coordonarea
3	Dependență - supraveghere	Pacientul necesită coordonarea verbală sau ajutor potențial din partea unei persoane fără contact fizic
4	Independență - pe teren plan	Pacientul poate merge independent pe teren plan, dar necesită ajutor la scări, pante sau suprafețe denivelate
5	Independență	Pacientul poate merge independent oriunde

Fig 6: FAC (Functional Ambulation Categories) international scale – utilised in our Clinic Division

Clinical/ Paraclinical evaluation

During hospitalisation, the patient presents some short episodes of: anaemia normochrome, relapsed urinary infections treated with specific antibiotics according to antibiograms and ocular and cutaneous allergy with erythema and itching that were treated with antihistaminic drugs and SAID injections.

On brain MRI appear space replacement processes located extra-nevraxial above and infratentorial at the level of bilateral ponto-cerebellar angles, intra-ventricular, at the level of the bilateral occipital horns at the level of the brain and at the level of the bilateral frontal meninges, in conclusion: NF-2 (schwannomas pontocerebellar, ependynomas - occipital horns and meningiomas).

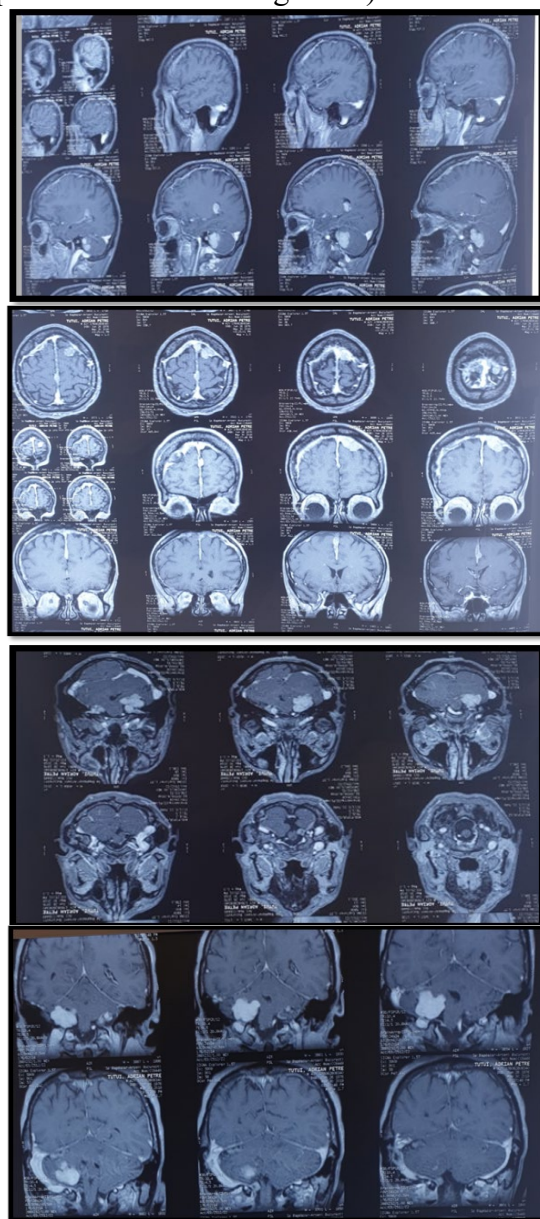


Fig 7,8,9,10 MRI examination of our patient: NF-2 (schwannomas pontocerebellar, ependynomas - occipital horns and meningiomas) ((from TEHBA Neuro-Rehabilitation Clinic Devision)

Interdisciplinary evaluation

Gamma knife evaluation: the patient is out of radiosurgery treatment recommendation; if he decides the neurosurgery of the right neurinoma, he can then benefit of gamma knife treatment on the tumoral residue.

Neurosurgery evaluation: multiple expansive intracranial processes without any important modification comparing to the last evaluation. Recommendation: repete the cerebral MRI in 6 months with a comparative evaluation with the last MRI; continue the rehabilitation program and a short term treatment (10days/ month) with steroid drugs.

ORL examination confirms NF-2, normal from otoscopy examination point of view, perception bilateral hearing loss, Recommendation: total audiogram.

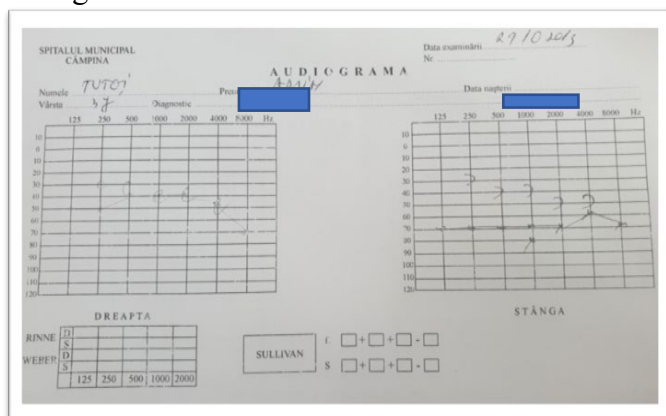


Fig. 11: ORL examination in our patient

Ophtalmological evaluation shows well- defined flat papillae, normal dilated, diminished calibre vessels.

Infectious disease specialist evaluation revealed a urinary tract infection with E. Coli and recommended 7 days Colistin 6mil/day treatment.

Diagnosis

Based on the anamnesis data, on the clinical examination and parclinical investigation the established diagnosis is the following:

- Incomplete paraplegia AIS/Franel C with T8 neurological level post intramedular thoracic tumor T7-T10 surgically treated (on 08.12.2018 and on 10.01.2019)
- Neurogenic bladder in remission
- Neurofibromatosis type 2 with:
- Multiple expansive intracranial processes (ponto-cerebellar schwannomas, meningiomas, and occipital ependymomas)
- Perception bilateral hearing loss
- Right vocal cord paralysis
- Relapsed urinary infections treated

Treatment

During hospitalization, the patient received complex drug treatment with: injectable anticoagulant and when he began mobilization at the kinetotherapy room antiagregant drugs, analgesics, NSAID, SAID, antibiotics, urinary antiseptics, gastric protector, vitamine C, antihistaminic drugs.

Kinetotherapy, initially only in bed (limited by the surgery restriction for 2 weeks) with a personalised program : passive movement at the joints level, active ones, active with lower limb resistance, correct positioning in bed for prevention of vicious joints positions or thrombophlebitis, and after that at the physical therapy room: exercises at MotoMed bicycle, lifting at stall bar bench, exercises on roller device, on pedal exerciser, walking through parallel bars first with an important help from the kinetotherapist.

Results

The patient benefited from a complex neuro-muscular rehabilitation program, having a favourable evolution, with an increase in the evaluated scales scores:

- AIS/ Frankel score from 74 motor to 80 points, and sensory score from 204 to 214 points → from AIS/ Frankel C to D
- Ashworth modified scale from 3 to 2
- FIM motor from 45 points to 74 points; cognitiv 35 points
- QoL from 66 points to 80 points
- WISCI from 0 points to 13 points
- FAC International Scale from 0 to 3

And he had as final performance, walking with a careframe for short distances as well as a sphincter re-education with the neurogenic bladder remission. The paraclinical assessments (cerebral and spinal cord MRI) detect multiple cerebral tumors and micro-nodules adjacent to the lumbar spinal roots, which, associated with the bilateral acoustic neurinoma (diagnosed in 2013), contributed to the confirmation of the NF2 diagnosis.

The patient had two admissions in our clinic division 25.01-21.03.2019 and 07.05-20.06.2019, benefited from a multidisciplinary team evaluation, complex neuro-muscular rehabilitation program, having a favourable evolution, with an increase in the evaluated scales scores, now performing walking with a support from another person in walking frame, as well as sphincter reeducation, with the neurogenic bladder remission.

Possible complications

- Associated with brain tumors: deafness, headaches, epilepsy, visual affections, respiratory and possible deglutition problems if the tumor grows.
- Associated with spinal tumors: becoming a complete paraplegic if another compressive spine tumor will appear.
- Increasing the pain and the tingling/numbness in the lower limbs
- Pressure sores

Prognosis

In our case the *ad vitam* prognosis – is reserved because of the localisation of the brain tumor, their increased dimensions and number and because of the possible complication including exitus.

Ad functionem prognosis is satisfying taking into account the patient's good evolution during neurorehabilitation program if he will continue the kinetotherapy.

Ad laborum prognosis is reserved, the patient being at the moment a wheelchair user and his profession is a construction worker.

An important fact is the medical control (neurorehabilitation, neurology, neurosurgery-gammaknife, ORL, ophtalmology), including MRI, at every 6 months for estimating the tumor growth and the appearance of possible complication.

Case particularity

The case particularity is the fact that the patient's symptomatology has both elements from NF-1 and NF-2 symptoms and they began at an older age than the one at which the disease usually begins'

The more important symptomatology began when the spinal tumor had developed, and after the first neurosurgery intervention including the fact that the symptoms generated by the brain tumors were amplifying as a consequence of marrow edema and subsequently of an increased cerebrospinal fluid pressure including after two general anesthesia procedures. The patient had a very good evolution after the second neurosurgery intervention and following the neuro-rehabilitation program.

Conclusion

Even if there is no cure for neurofibromatosis and no standard treatment, it is important to promptly diagnose such a rare disease and to give an adequate treatment (NSAID/ SAID or other analgesic drugs, surgery, chemotherapy or radiation –when it's needed, or psychotherapy) for controlling symptoms and also a personalized rehabilitation program (including nursing measures) enhancing including patient's quality of life (18).

References

1. Ghalayani P, Saberi Z, and Sardari F, Neurofibromatosis type I (von Recklinghausen's disease): A family case report and literature review, *Dent Res J (Isfahan)*. 2012 Jul-Aug; 9(4): 483–488, PMID: 23162593
2. Kostić K, Dinić M., Mijušković Z., Zolotarevski L., Kandolf-Sekulovic L, Zečević R., Neurofibromatosis type I (von Recklinghausen's disease): A report of three cases, *Serbian Journal of Dermatology and Venereology* 2011; 3 (2): 77-82, DOI: 10.2478/v10249-011-0040-x
3. <https://emedicine.medscape.com/article/1177266-differential>
4. https://en.wikipedia.org/wiki/Neurofibromatosis_type_II
5. Striedinger K, VandenBerg SR, Baia GS, McDermott MW, Gutmann DH, Lal A (November 2008). "The neurofibromatosis 2 tumor suppressor gene product, merlin, regulates human meningioma cell growth by signaling through YAP". *Neoplasia*. 10 (11): 1204–12. doi:10.1593/neo.08642. PMC 2570596. PMID 18953429.
6. Stamenkovic, I; Yu, Q (2010). "Merlin, a "magic" linker between extracellular cues and intracellular signaling pathways that regulate cell motility, proliferation, and survival". *Current Protein & Peptide Science*. 11 (6): 471–84. doi:10.2174/138920310791824011. PMC 2946555.
7. <http://advocurenf2.org/nf2-signs-and-symptoms>
8. <https://rarediseases.org/rare-diseases/neurofibromatosis-2/>
9. Evans DG, Huson SM, Donnai D, et al. A clinical study of type 2 neurofibromatosis. *Q J Med* 1992;84:603–618.
10. <https://www.webmd.com/pain-management/neurofibromatosis#3>
11. Jean Régis; Pierre-Hugues Roche (2008). *Modern Management of Acoustic Neuroma*. Karger Publishers. pp. 191–. ISBN 978-3-8055-8370-1. Retrieved 20 December 2010.
12. https://www.stepwards.com/?page_id=6940
13. Neurofibromatosis Information Page". National Institute of Neurological Disorders and Stroke. Retrieved June 16, 2019.
14. <http://neuroradiologyteachingfiles.com/lia.html>
15. <https://rarediseases.info.nih.gov/diseases/7193/neurofibromatosis-type-2>
16. Evans DG. Neurofibromatosis type 2. *UpToDate*. April 2015;
17. <http://www.healthcommunities.com/neurofibromatosis/prognosis.shtml>
18. Munteanu Constantin, Munteanu Diana, Hotetiu Mihail, Dogaru Gabriela - Balneotherapy – medical, scientific, educational and economic relevance reflected by more than 250 articles published in *Balneo Research Journal*, *Balneo Research Journal*. 2019;10(3):174–203 Full Text DOI 10.12680/balneo.2019.257