

Particularities of complex therapeutically-rehabilitative management, stepwise, in a patient with post-CCT psycho-cognitive impairment in a large polytraumatic context - case report

POPESCU Laura Georgiana ¹, NIRLU Luminița ¹, ALBEȘTEANU Ana Carmen ¹,
SAGLAM Ali Osman ¹, STAVRICĂ Alexandru ¹, ONOSE Gelu ^{1,2}

Corresponding author: POPESCU Laura Georgiana, E-mail: laurapopescy@yahoo.com

1. Teaching Emergency Hospital "Bagdasar-Arseni" (TEHBA), Bucharest, Romania
2. University of Medicine and Pharmacy "Carol Davila" (UMPCD), Bucharest, Romania

Abstract

The subject matter of the present scientific paper is the report of a sustained, sequential, stage-adjusted and persistent therapeutic rehabilitation team-run program over a relatively short period of time in the case of a polytraumatized patient with severe TBI (GCS=4), multiple pelvic fractures, right clavicle fracture, incomplete fracture of the left transverse apophysis L5 - unoperated, perivesical hematoma, thoraco-abdominal contusion, neurogenic bladder and antero-retrograde amnesia related to trauma that led to a favorable progression despite the contraindication of sitting positioning and the mental state of the patient during hospitalization.

Key words: *neuromuscular rehabilitation, cranio-cerebral trauma, pelvic fracture, polytraumatism, antero-retrograde amnesia related to trauma,*

Introduction

Cranio-cerebral trauma (CCT) or traumatic brain injury (TBI), associated with other lesions occurring in polytraumatic context, is the most commonly encountered neurological pathology with vital risk in younger patients, often the consequence of road accidents. (1)

Traumatic brain injury (TBI) is a nondegenerative, noncongenital insult to the brain from an external mechanical force, possibly leading to permanent or temporary impairment of cognitive, physical, and psychosocial functions, with an associated diminished or altered state of consciousness(2) Severe TBI is indicated when the GCS score is below 9 within 48 hours of the injury (3,5,6)

Method: case presentation

The informed consent of the family and the approval of the Ethics Commission of „Bagdar-Arseni Hospital” in Bucharest (N.O. 14646/14.06.2019) were obtained for the communication of this case.

We present the case of a 20-year-old male patient who suffered a road accident at the beginning of 2019. On February 9, 2019, the patient is admitted in the department of neurosurgery. At the time of the first medical contact the clinical and imaging examination revealed: loss of consciousness (GCS=4), multiple pelvic fractures, right clavicle fracture, incomplete fracture of the left transverse apophysis L5, perivesical hematoma, thoraco-

abdominal contusion and neurogenic bladder. An intracranial pressure sensor is mounted and the patient is moved to the anesthesia and intensive care unit, where he has a favorable progression of the head trauma. On February 16, 2019, after stopping the analgesic and sedative treatment, the patient is temporospatially disoriented and becomes psychomotor agitated. On February 18, 2019, following the psychiatric evaluation, behavioral disinhibition is found, associated with the impossibility of maintaining and focusing attention. On March 18, 2019, the patient is admitted in the department of neuromuscular recovery for psycho-cognitive status with antero retrograde amnesia post severe TBI (GCS=4) in polytraumatic context, sensitivity disorders in the right hand and foot, severe locomotor dysfunction and self-care, ability impairment. He was in a relative good general state, afebrile and had poorly represented adipose connective tissue. At the level of the skin and mucous membranes he presented a right frontal scar (with suture thread) and a panaritium of the right thumb. Osteo-articular system was apparently integer, except multiple pelvic fractures, right clavicle fracture, incomplete fracture of the left transverse apophysis L5 - unoperated. The patient was equilibrated from a cardiovascular, respiratory, digestive and renal point of view with oxygen saturation of 98% spontaneously, blood

pressure of 90/70 mmHg and heart rate of 84 rhythmic beats per minute. At the time of admission, the patient had a fixed permeable urine probe. Regarding the neuromioarthrokinetic examination the patient was partially conscious, partially cooperative, psychomotor agitated, temporally, spatially, auto and allopsychically disoriented and presented antero-retrograde amnesia. Osteotendinous reflexes were sharpened in the lower limbs bilaterally. The patient presented sensitivity disturbances in the right hand and foot and pathological reflexes (Babinski sketched bilaterally). Motor control was present with muscle strength of 3+/5 MRC on all levels (proximal, intermediate and distal) at the left superior and inferior limb and 4/5 on all levels at the right superior and inferior limb. Clinico-functionally, the patient kept resting in bed, posturing into the wheel chair was non-recommended, given the multiple pelvic fractures. The patient was clinically and functionally assessed, according to the standardized protocols implemented in our clinic by means of the assessment grading scales: FAC (Functional Ambulation Category) = 2, FIM (Functional Independence Measure) cognitive = 26, FIM motor = 47, Modified Rankin Scale = 4, The Glasgow Outcome Scale Extended (GOS-E) = 3, Asworth = 4, Penn = 0, QoL (Quality of Life) (Flanagan completed by Burckhard) = impossible to test at admission, MMSE (Mini-mental state examination) = impossible to test at admission, MoCA (Montreal - Cognitive Assessment) = impossible to test at admission.

The patient was paraclinically examined in order to evaluate his biological reserve and his availability in bearing the recovery program. To this purpose, both laboratory and imaging investigations have been used.

The thoracic pulmonary radiography (Fig. No.1) showed no signs of acute or evolutionary pleuropulmonary lesions.

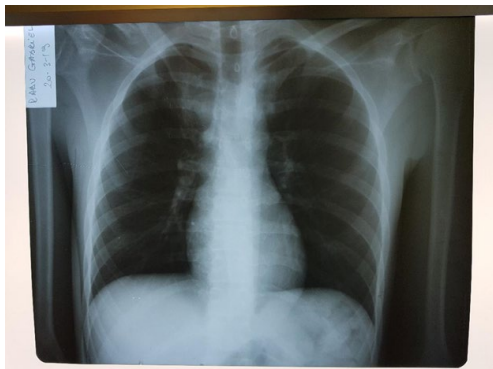


Figure No. 1 - Thoracic-pulmonary radiography

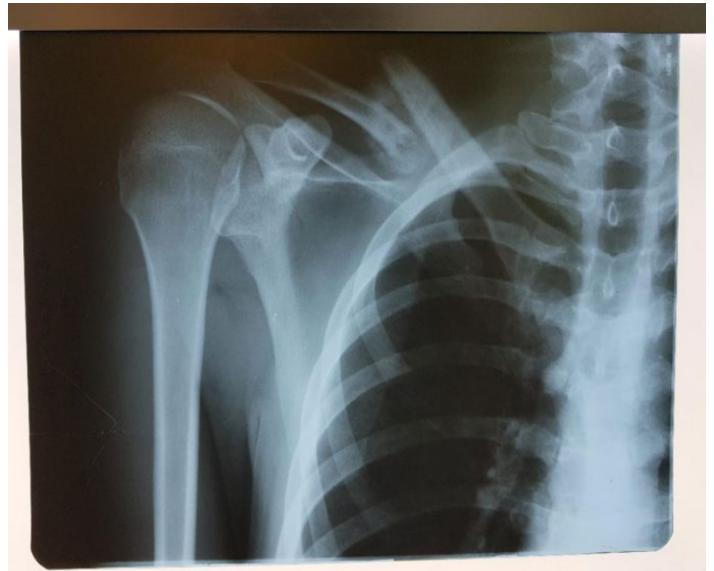

Figure No. 2 - Right clavicular radiography

Right clavicular radiography (Fig. No.2) showed an old right middle-clavicular fracture with displacement and vicious calyx.

On the pelvic radiography (Fig. No.3) could be seen complete bilateral fracture of the superior pubic arch and left side complete fracture of the inferior pubic arch.

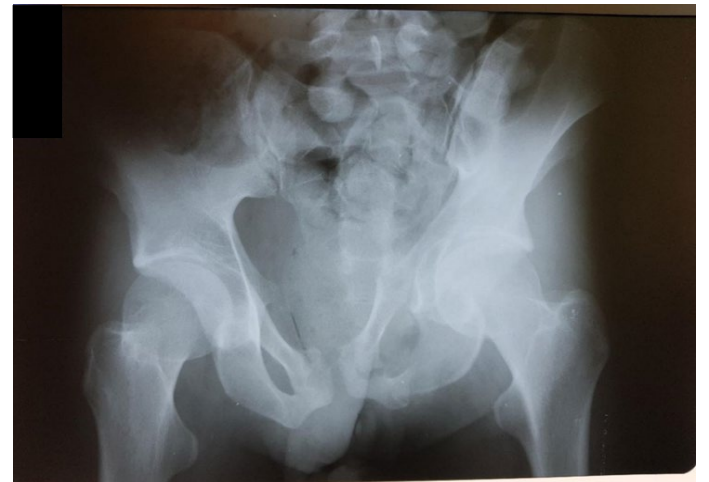

Figure No. 3 - Pelvic radiography

A bone CT scan (Fig. No. 4, Fig. No.5) was also performed for a better visualization of the pelvic fractures, necessary to evaluate the possibility of mobilizing the patient. The result showed multiple fractures: comminutive fracture of the left sacral wing with the interest of conjugation holes S1, S2 and S3; left S1 apophyseal fracture; bilateral acetabular comminutive fracture; fracture of both pubic branches adjacent to the symphysis; left ischiatic comminutive fracture; right ischial fissure; left L5 transverse apophyseal fracture.

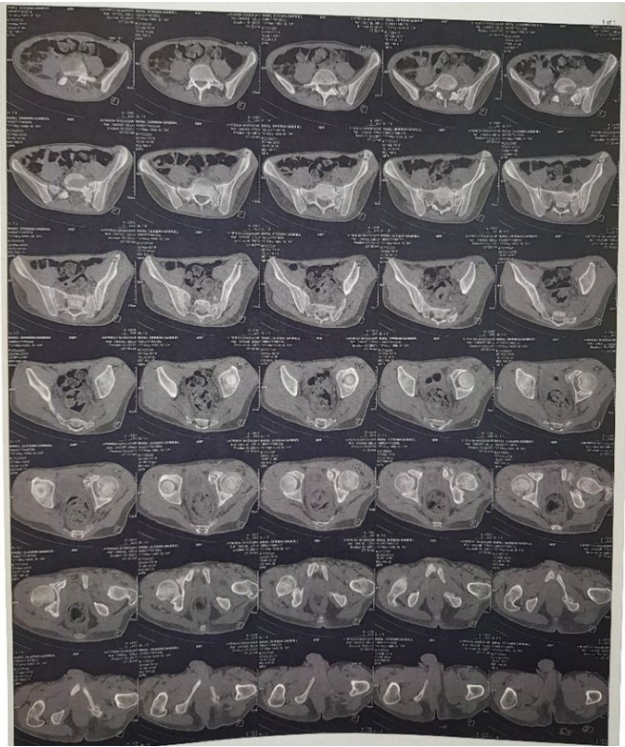

Figure No. 4 - Pelvic bone CT scan

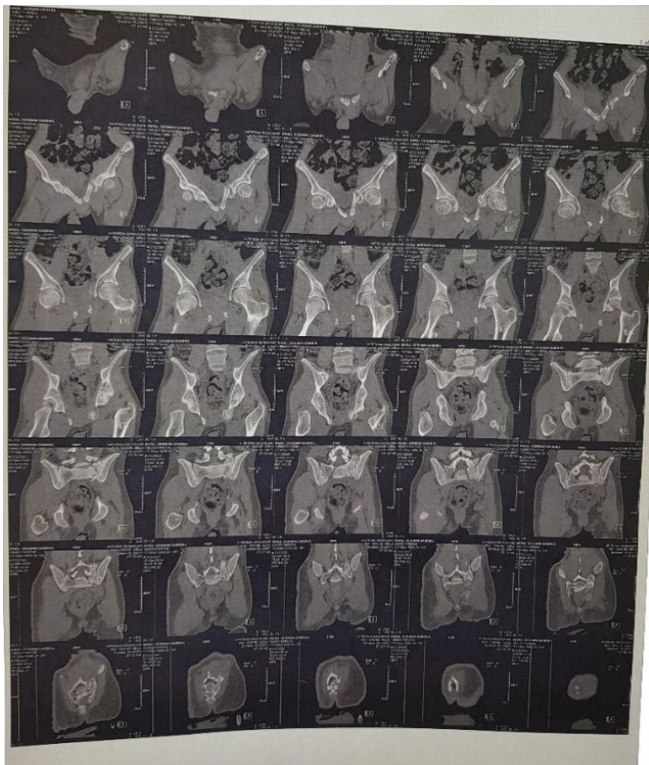

Figure No. 5 - Pelvic bone CT scan

The results of brain computed tomography investigation (Fig. No. 6) revealed craniocerebral lesions: right frontal subdural hematoma with a thickness of 5 - 6 mm, left frontal hygroma, without deviation from the midline.

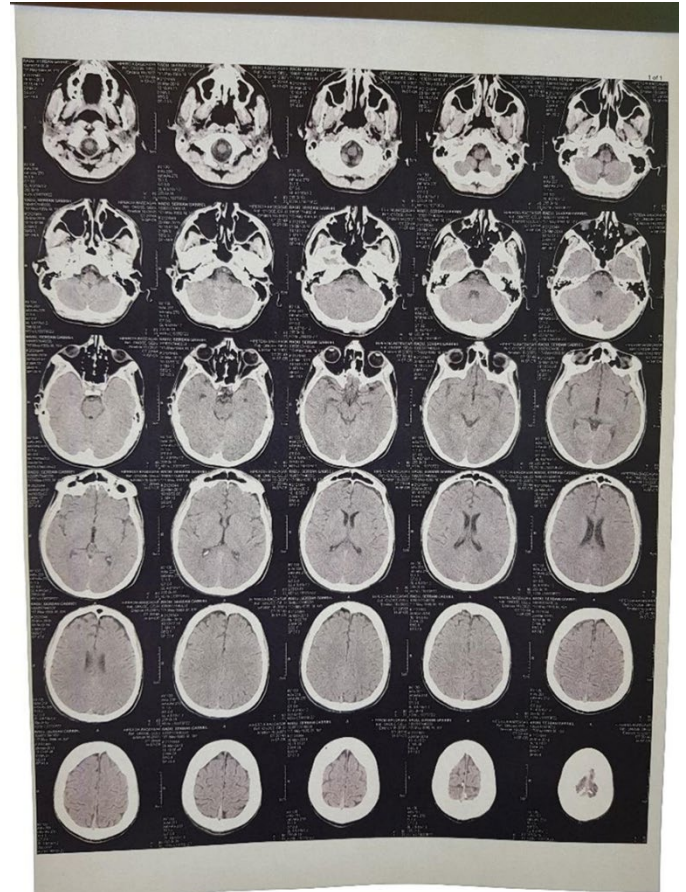


Figure No. 6 - Brain CT scan

After the clinical and paraclinical investigation of the patient (who revealed hepatic cytolysis syndrome - ALT (TGP) = 92U/L; AST (TGO) = 44U/L -, mild normochromic and normocytic anemia, moderate eosinophilia) the diagnosis at admission and at 72 hours was established: „Psychocognitive status, impairment of ability and relatively mild sensitivity disorders hyperesthesia type at the right limbs after severe traumatic brain injury (GCS = 4) in polytraumatic context (road accident - driver 9.02.2019): vicious consolidated right clavicle fracture (radiological aspect), multiple pelvic fractures (unoperated, undergoing consolidation), perivesical hematoma remitted, thoracic-abdominal contusion remitted. Neurogenic bladder (fixed urinary tract carrier). Purulent sinusitis (MRI imaging). Panaritium at the right thumb”.

The main general objectives of the neurorehabilitation program were: combating pain and regaining functionality that allows the patient self-grooming and locomotion, treating the associated orthopedic diseases and preventing complications, improving the patient's psycho-

cognitive, mental and emotional status and obtaining socio-professional, respectively family reestablishment in order to improve patient's quality of life (4,5,6).

Evolution

During the hospital stay, the patient underwent a complex recovery program which included pharmaceutical treatment with: injectable anticoagulant type HGMM, anti-platelet aggregation, neurotrophic, xanthine oxidase enzyme inhibitor, pain reliever for neuropathic pain calcium channel blocker, antidepressant, anxiolytic, urinary antiseptics, gastric protector, COX 2 receptor inhibitor; physical treatment (kinesiotherapy) and psychotherapy. The recovery team collaborated with other specialists to provide the patient with a complete, individualized recovery plan, based on the particularities of the case.

For managing the psycho-cognitive and mental status, the neurologist, the psychiatrist and the psychologist were consulted repeatedly. In addition to the psychiatric treatment administered for anxiety and the episode of reactive depression, multiple psychotherapy sessions were required, especially in the context in which the patient lost family members in the road accident suffered.

In order to mobilize the patient, the recovery team consulted both the neurosurgeon and the orthopedist. The mobilization was made gradually, with postural support in orthostatism and avoiding sitting position. The physical-kinetic rehabilitation program included the prevention of amyotrophy, maintenance of joint mobility and quality of articular movement, reeducation of the patient's orthostatic posture, teaching the patient to perform the transfer from bed to orthostatic position, avoiding the sitting position and relearning of the fine motor skills of the wrists, hands and fingers.

For the treatment of the sinus rhinitis revealed at imaging examination (MRI) an otolaryngologist was consulted. Plastic surgery specialist consulted the patient in order to evaluate the possibility of a surgery at the right thumb level to treat the panaritis. The procedure was carried out on April 8, 2019.

Results

The patient remained afebrile, cardio-respiratory balanced throughout the hospital stay and had a favorable evolution from a pain-dysfunctional point

of view: marked improvement, with the patient verticalization, maintaining orthostatism and independent mobilization over long distances. Muscular strength improved to 5/5 MRC on all levels, right and left limbs. A marked improvement was also recorded regarding the psycho-cognitive, mental and emotional status. After one month in our clinic, before discharge, the results of the recovery program were evaluated using the same scales applied at the admission (Table No.1).

Scale	Admission	Discharge
FAC	2	4
FIM cognitive	26	35
FIM motor	47	85
GOS-E	3	6
Rankin	4	2
Asworth	0	0
Penn	0	0
QOL	impossible to test	96
MMSE	impossible to test	26
MoCA	impossible to test	25

Table No.1 - Evaluation scales at admission and discharge

3 months after discharge, the patient returned to our clinic for a checkup, on which occasion he attended sessions of ergotherapy for the ability impairment.

According to the data provided by the patient at the last hospitalization, he had no difficulties in functioning independently at home, he re-enrolled at the university and even started a romantic relationship.

The MRI performed during the second hospitalization highlighted the damage of the central white matter, lesions with a sequel aspect at the level of the calyx body.

Prognosis

The patient's prognosis is favorable (at vitam: favorable, at functionem: favorable, at laborem: favorable), provided that the recommendations from the discharge will be respected (continuing the recovery program according to the instructions given at discharge, including avoiding the sitting position until the consolidation of the pelvic fractures, regular check-up at our clinic).

Conclusions

The combined and complex rehabilitation led to a complete cognition remission and complete locomotor regaining at discharge, the patient progressed from psycho-cognitive status after severe TBI (GCS=4) in polytraumatic context associated with antero-retrograde amnesia related to trauma and severe locomotor and self-care dysfunction to psycho-cognitive status in marked improvement, with the patient verticalization, maintaining orthostatism and independent mobilization over long distances.

The favorable progression emerged after a sustained, sequential, stage-adjusted and persistent therapeutic rehabilitation team-run program over a relatively short period of time, in the context of both the contraindication of sitting positioning and the mental state of the patient during hospitalization.

References

1. Dewan, M. C., Rattani, A., Gupta, S., Baticulon, R. E., Hung, Y., Punchak, M., Agrawal, A., Adeleye, A. O., Shrivastava, M. G., Rubiano, A. M., Rosenfeld, J. V., & Park, K. B. (2018). Estimating the global incidence of traumatic brain injury, *Journal of Neurosurgery JNS*, 130(4), 1080-1097. Retrieved Oct 27, 2019, from <https://thejns.org/view/journals/j-neurosurg/130/4/article-p1080.xml>
2. „TBI Traumatic Brain Injury, Definition, Epidemiology, Pathophysiology” Dawodu ST, <http://medicine.medscape.com/article/326510> overview updated Jun 27, 2019.
3. Foulkes MA, Eisenberg HM, Jane JA, et al. The Traumatic Coma Data Bank: design, methods, and baseline characteristics. *J Neurosurg*. 1991. 75:S8-S13
4. Ghid de diagnostic/evaluare, principii terapeutice și neuroreabilitare în suferințe după traumatisme craniocerebrale. Prof. Dr. Gelu Onose, Ș.L. Dr. Aurelian Anghelescu.
5. Munteanu Constantin, Munteanu Diana, Hoteteu Mihail, Dogaru Gabriela - Balneotherapy – medical, scientific, educational and economic relevance reflected by more than 250 articles published in *Balneo Research Journal*, *Balneo Research Journal*. 2019;10(3):174–203 Full Text DOI 10.12680/balneo.2019.257
6. Munteanu Constantin (149) Cell biology considerations in Spinal Cord Injury – Review, *Balneo Research Journal*. 2017;8(3):136-151, DOI 10.12680/balneo.2017.149