

NICULA Cristina ^{1,2}, SUCIU Corina ², BULBOACĂ Adriana Elena ³

Corresponding author: Cristina Nicula, E-mail: niculacristina65@yahoo.com



- ¹. University of Medicine and Pharmacy “Iuliu Hațieganu”, Faculty of Medicine, Department of Ophthalmology, Cluj-Napoca, Romania
². Emergency County Eye Hospital, Cluj-Napoca, Romania
³. University of Medicine and Pharmacy “Iuliu Hațieganu”, Faculty of Medicine, Department of Pathophysiology, Cluj-Napoca, Romania

Abstract

An 46-year-old Caucasian woman was diagnosed with idiopathic intracranial hypertension (IIH) after presenting with papilledema and bilateral visual blurring. Lumbar puncture revealed an opening pressure of more than 550 mmH₂O. Cerebral magnetic resonance imaging (MRI) showed bilateral flattening of the posterior sclera, enhancement of the prelaminar optic nerve, distension of the perioptic subarachnoid space, intraocular protrusion of the prelaminar optic nerve and empty sella. The main purpose of the treatment was to release the symptoms and preserve the vision. It was initiated the general treatment with Mannitol 20%, 250 ml/day, Acetazolamide 2x500 mg/day and B-vitamins. After discharge the patient followed a treatment with acetazolamide 2x250 mg/ daily doses and oral potassium supplements 30 mg bid/day.

Key words: *pseudotumor cerebri, idiopathic intracranial hypertension, papilledema,*

Introduction

Pseudotumor cerebri is a rare condition which is characterized by an idiopathic increased intracranial pressure (IIP) manifested with papillary edema and other neurologic signs such as headache, visual loss, tinnitus, diplopia. Often this syndrome appear in young overweight women of childbearing age. The funduscopy reveal bilateral papilledema. Visual field examination by perimetry and ocular coherence tomography are important examination for the diagnostic. Because the symptoms are similar to cerebral mass lesion, for this reason the name of pseudotumor cerebri was associated with “false brain tumor”. The diagnosis is an exclusion one, other causes of increased intracranial pressure (ICP) have to be excluded with imaging methods (brain MRI) and lumbar puncture. The main purposes of treatment are releasing of the symptoms and conservation of vision. Treatment options for this potentially low vision disease include diet and life style, certain medications (e.g., vitamin A derivatives, tetracycline, and lithium), carbonic anhydrase inhibitor (Acetazolamide or Diamox) (1), steroids (2), Furosemide (3). In case of medical treatment failure, surgical treatment is indicated. Cerebrospinal fluid shunting (CSF) (e.g., ventriculo-peritoneal and lumbar-peritoneal shunting) (4-8) and optic nerve sheath fenestration (ONSF) (9-16), and management of transverse sinus stenosis are indicated (17).

Case report

We present the case of a 46 year old female patient, known with ovarian cyst, asthma, who was admitted in our department accusing ocular discomfort in both eyes felt as retro bulbar pressure. The patient reported no allergies and no fever in the past days. The onset of these symptoms started 2 months before the presentation in our department. The family history was not relevant. She had no chronic treatment. The general clinical exam was normal. The body mass index was normal. She did not have any history of recent ear infection, treatment for acne vulgaris, vitamin A supplementation, lead exposure, seizure disorder, oral contraceptives, steroid intake or withdrawal. There was no history of tick bites, target rash or joint pains. Her medical, surgical and family history was all unremarkable. The ocular examination at the presentation in our department revealed a best corrected visual acuity of 1 without correction in both eyes. The refraction showed at right eye: +0,75D sph-0.25 D cyl ax 150° and at left eye: +0.75 D sph, 0.25 D cyl, ax 10°. The intraocular pressure was 17 mmHg measured by aplanotometry in both eyes. The light perception and projection was present at both eyes. The papillary light reflex was present in both eyes. The ocular motility was normal. Slit lamp examination revealed a normal examination in both eyes.

The ophthalmoscopy of both eyes showed at both eyes papilledema, the optic nerve head without edges, prominent, dilated retinal veins and a chrysanthemum flower appearance in the right eye (RE).(Fig.1).

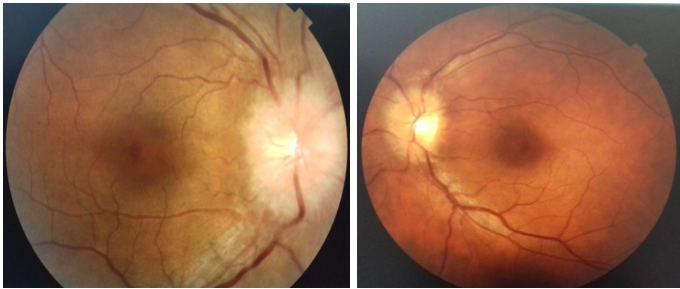

Fig.1. Ophthalmoscopy aspect seen at retinophotography at RE and LE

The visual field examination discovered enlarged blind spot both eyes with some paracentral scotoma in both eyes.(Fig 2).




Fig.2. Visual field aspect in both eyes

The optical coherence tomography (OCT) of the optic nerve revealed a swollen optic nerve in both eyes but no retinal nerve damage. (Fig.3).

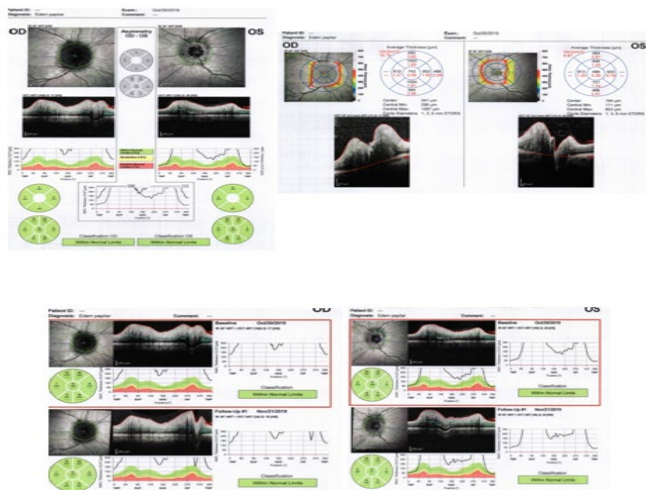


Fig. 3. OCT aspect at both eyes

Other examinations:

The standard blood tests were within normal parameters: RBC= 4,60 x 10¹²/L, hemoglobin = 13,6 g/dL, WBC= 5,18x10⁹/l, creatinine = 0,68 mg/dL, blood glucose =104 mg/dL, CRP= 0,27 mg/dL, BUN=30 mg/dL, fibrinogen= 316 mg/dL, platelets= 245x10⁹/l, erythrocyte sedimentation rate =3 mm/h. Antibodies IgG anti-Borrelia and IgM anti-Borrelia, anti-RNP, anti-SSA, anti-cardiolipin, p-ANCA, c-ANCA, antiSCL70, anti-mitochondrial, ANA and the circulating immune complexes were normal. The serum vitamin B12 was 251 pg/ml and folic acid 15,17 ng/ml. Thyroid tests were normal. No inflammatory markers were positive.

The neurologic examination concluded a conscious patient, temporal and spatial oriented, symmetrical and reactive pupils, normal eye movements, no meningeal signs, with no cranial nerve deficits, no motor deficit, normal tendon reflexes, slightly brisk in the lower limbs, no Babinski's sign present, no ataxia, no sensitivity disorders, no sphincter disorders. The recommended treatment was Mannitol 20% 100 ml/day iv, neurotrophics and B1 (100 mg/day), B2 (10 mg/2 ml/ day) and B6 (50 mg/2ml/day) vitamins.

The cerebral magnetic resonance imaging (MRI) examinations revealed signs of idiopathic intracranial hypertension and few small focal lesions suggestive for demyelinating disease.(Fig.4).

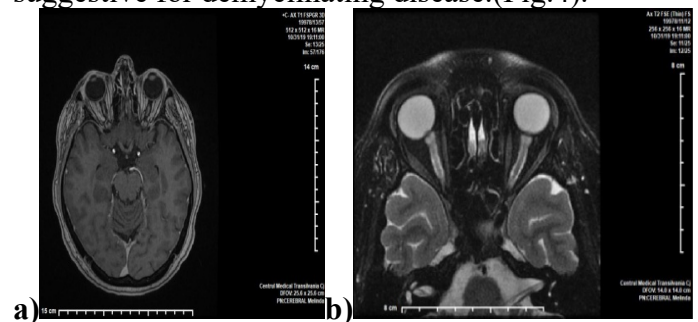


Fig.4. (a) - Brain MRI aspect T1W + contrast axial images at the level of the optic nerve(ON) reveal bilateral tortuous ON with prominent cerebrospinal fluid spaces around the ON.

(b) - T2-W1sequence reveal- flattening of the posterior sclera, bilateral hyperintensity and swelling of the optic nerve.

Lumbar puncture was done and the opening pressure was 550mmH₂O. Examination of cerebrospinal fluid (CSF) composition revealed normal cell count and differential glucose and protein.

The positive diagnose for both eyes was: papillar oedema, mild hyperopia, idiopathic increased intracranial pressure, folic acid deficiency.

The differential diagnosis for a bilateral papillary edema included structural cerebral lesions such as cerebral tumors (benign or malignant), vascular lesions, inflammation / infections (cerebral abscess), all which were ruled out by the neurologic examination and by the cerebral MRI examination. Because all the inflammatory tests were negative an autoimmune was excluded.

Chronic intracranial hypertension can be caused by many conditions including certain drugs such as tetracycline, a blood clot in the brain, excessive intake of vitamin A, or brain tumor. It can also occur without a detectable cause excluded by medical history of the patient.

Treatment

The main purpose of the treatment was to release the symptoms and preserve the vision. During the hospitalization, because of the mild visual field loss it was initiated the general treatment with Mannitol 20% 250 ml/day, Acetazolamide 2x500 mg/day, B1 (100 mg/day), B2 (10 mg/2 ml/ day) and B6 (50 mg/2ml/day) vitamins.

The evolution was stable during the admission. Recommendations at hospital discharged were to avoid the physical effort and indicated the treatment with Acetazolamide 2x250 mg/ daily doses and oral potassium supplements 30 mg bid/day.

The follow-up examination at one and 6 months after discharge showed a maximum visual acuity without correction at both eyes. The ophthalmoscopy exam revealed bilateral mild papillar oedema. The visual field examination revealed mild modifications (enlarged blind spot and few paracentral small scotomas) (Fig.5).




Fig.5. - Visual aspect at both eyes -6 months follow-up. Enlarged blind spot and few paracentral small scotomas.

Discussion

Idiopathic increased intracranial pressure (IICP), called also benign intracranial hypertension is a demanding disorder which is leading to increased intracranial pressure (ICP), in the absence of identifiable cause (18,19). The incidence of the condition is estimated to be 20 per 100,000 (20) and it is expected to increase rapidly. There are studies which showed that obesity is the main underlying etiological factor, knowing that obesity can affect children and males to a similar degree as females (21-23). What is interesting that our patient was not obese not fulfilling the profile for IIP.

At presentation, the most common symptom is headache (24,25) which is pulsatile in over 80% of patients (26) and 70% of patients report a focal component of the headache (e.g. occipital or retro-orbital pain)(26). After the decrease of intracranial pressure (ICP) the headache can be improved. Sometimes when patients have coexisting headache disorders (18) it may not respond well to treatment that decrease ICP and require conventional agents (pain relievers drugs) to control the symptom (19). In our case the headache was not so severe, had retro-orbital location but it was associated with papilledema.

Visual symptoms are common in IICP and are linked with papilledema. The common sign is represented by bilateral papilledema, sometimes symmetric sometimes asymmetric. Papilledema is present in 97% of IICP cases and is the hallmark features of the illness (27). In the absence of papilledema, abducens nerve palsy is a major criteria for the positive diagnosis of IICP (28). In our case, the abduces paralysis was absent.

The patients complain about transient visual loss precipitated by postural changes and Valsalva procedure –like maneuvers with duration of few seconds. The visual disturbances were present as progressive and early changes of visual field, enlargement of blind spot and a nasal step defect in visual field examination. In the late stages, if the papilledema persists, nasal defects, arcuate defects and severe visual field constriction can appear (29). Visual acuity is not decreased if visual field examination does not reveal any disturbances. That is why the examination of visual field by static perimetry is essential to establish management decision.

Abducens nerve palsy may be another sign in IIP and is due to the increased ICP on this nerve, which

has the longest intracranial pathway (25). Abducens nerve palsy was not present in our case.

Some authors revealed the possible correlation between IICP and iron-deficiency anemia (30). In our case, the patient did not present this type of anemia.

MRI has been of particular interest linked with the ability to provide the visualization of eyeball, optic nerve, orbit and optic tract.(31). Increased ICP may lead to several abnormalities on MRI, including: flattening of the posterior sclera, enhancement of the prelaminar optic nerve ; distension of the perioptic subarachnoid space, intraocular protrusion of the prelaminar optic nerve and empty sella (31).

Without any treatment, papilledema can cause progressive irreversible visual loss and optic atrophy. The principle objectives of treatment are reduction of symptoms, including headache, and preservation of vision. All overweight patients should be encouraged to enter a weight-management program with a goal of 5% to 10% weight loss, along with a low-salt diet. In our case the patient was not obese which represent a particularity of the case. We initiated a medical treatment with Acetazolamide in order to reduce the papilledema. When symptoms and visual loss are mild a lot of medical and surgical treatments are recommended.

In cases of mild visual field loss, as it was in our case, the treatment with Acetazolamide has to be initiated. Acetazolamide, a carbonic anhydrase inhibitor, decrease the cerebrospinal fluid production and decrease the ICP (32). Steroids were commonly used in the past for treating IIP but because of several side effects such as weight gain, rebound intracranial pressure after withdrawal, increase of glycemia, osteoporosis, psychosis ,peptic ulcer disease, hypertension, renal failure should not be used routinely (33,34).

Lumbar puncture improves the symptoms of IIP in most cases for a short period (35, 36). In our case the patient felt better after the procedure although the headache was not typically for IIP from the very beginning.

When visual loss is more severe or rapidly progressive, surgical interventions, such as optic nerve sheath fenestration or cerebrospinal fluid shunting, may be required to prevent further irreversible visual loss. Various other ophthalmologic pathologies have to be considered for young patients, as causes of visual function deterioration. The choice of intervention depends on the severity of symptoms and visual loss (37, 38).

The optic nerve sheath fenestration is reserved for cases with vision loss secondary to papilledema and mild symptoms of ICP. The cerebrospinal fluid shunting is preferable in patients with visual loss due to papilledema and increased symptoms of ICP (29).

Conclusion. Our case showed an uncommon presentation of IIP with a headache localized retro-bulbar, with bilateral papilledema (more severe at RE) and absence of obesity, iron-deficiency anemia and abducens nerve paralysis.

Informed consent. An informed consent was obtained from the patient included in this article

Conflict of interest. Authors declare no conflict of interest.

References

1. Ball AK, Howman A, Wheatley K, et al. A randomised controlled trial of treatment for idiopathic intracranial hypertension. *J Neurol.* 2011;258:874–881.
2. Thambisetty M, Lavin PJ, Newman NJ, Biousse V. Fulminant idiopathic intracranial hypertension. *Neurology.* 2007;68:229–232.
3. Schoeman JF. Childhood pseudotumor cerebri: clinical and intracranial pressure response to acetazolamide and furosemide treatment in a case series. *J Child Neurol.* 1994;9:130–134.
4. Johnston I, Besser M, Morgan MK. Cerebrospinal fluid diversion in the treatment of benign intracranial hypertension. *J Neurosurg.* 1988;69:195–202.]
5. Rosenberg ML, Corbett JJ, Smith C, et al. Cerebrospinal fluid diversion procedures in pseudotumor cerebri. *Neurology.* 1993;43:1071–1072.
6. Eggenberger ER, Miller NR, Vitale S. Lumboperitoneal shunt for the treatment of pseudotumor cerebri. *Neurology.* 1996;46:1524–1530.
7. Burgett RA, Purvin VA, Kawasaki A. Lumboperitoneal shunting for pseudotumor cerebri. *Neurology.* 1997;49:734–739.
8. Maher CO, Garrity JA, Meyer FB. Refractory idiopathic intracranial hypertension treated with stereotactically planned ventriculoperitoneal shunt placement. *Neurosurg Focus.* 2001;10:E1.
9. Corbett JJ, Nerad JA, Tse DT, Anderson RL. Results of optic nerve sheath fenestration for pseudotumor cerebri: the lateral orbitotomy approach. *Arch Ophthalmol.* 1988;106:1391–1397.
10. Sergott RC, Savino PJ, Bosley TM. Modified optic nerve sheath decompression provides long-term visual improvement for pseudotumor cerebri. *Arch Ophthalmol.* 1988;106:1384–1390.

11. Berman EL, Wirtschafter JD. Improvement of optic nerve head appearance after surgery for pseudotumor cerebri. *JAMA*. 1992;267:1130.
12. Kelman SE, Heaps R, Wolf A, Elman MJ. Optic nerve decompression surgery improves visual function in patients with pseudotumor cerebri. *Neurosurgery*. 1992;30:391–395.
13. Chandrasekaran S, McCluskey P, Minassian D, Assaad N. Visual outcomes for optic nerve sheath fenestration in pseudotumor cerebri and related conditions. *Clin Experiment Ophthalmol*. 2006;34:661–665.
14. Yazici Z, Yazici B, Tuncel E. Findings of magnetic resonance imaging after optic nerve sheath decompression in patients with idiopathic intracranial hypertension. *Am J Ophthalmol*. 2007;144:429–435.
15. Wilkes BN, Siatkowski RM. Progressive optic neuropathy in idiopathic intracranial hypertension after optic nerve sheath fenestration. *J Neuroophthalmol*. 2009;29:281–283.
16. Kaye AH, Galbraith JE, King J. Intracranial pressure following optic nerve decompression for benign intracranial hypertension. *J Neurosurg*. 1981;55:453–456.
17. Fridley J, Foroozan R, Sherman V, Brandt ML, Yoshor D. Bariatric surgery for the treatment of idiopathic intracranial hypertension. *J Neurosurg*. 2011;114:34–9.
18. Friedman D. The pseudotumor cerebri syndrome. *Neurol Clin*. 2014;32: 363–396.
19. Friedman D., Liu G., Digre K. Revised diagnostic criteria for the pseudotumor cerebri syndrome in adults and children. *Neurology*. 2013;81: 1159–1165.
20. Friedman D., Rausch E. Headache diagnoses in patients with treated idiopathic intracranial hypertension. *Neurology*. 2002; 58: 1551–1553.
21. Radhakrishnan K., Ahlskog J., Cross S., Kurland L., O’Fallon W. Idiopathic intracranial hypertension (pseudotumor cerebri). Descriptive epidemiology in Rochester, Minn, 1976 to 1990. *Arch Neurol*. 1993;50: 78–80.
22. Bruce B., Kedar S., Van Stavern G., Monaghan D., Acierno M., Braswell R., et al. Idiopathic intracranial hypertension in men. *Neurology* .2009;72: 304–309.
23. Standridge S. Idiopathic intracranial hypertension in children: a review and algorithm. *Pediatr Neurol* . 2010;43: 377–390.
24. Giuseffi V, Wall M, Siegel PZ, Rojas PB. Symptoms and disease associations in idiopathic intracranial hypertension (pseudotumor cerebri): a case-control study. *Neurology*. 1991;41:239–244.
25. Wall M., Kupersmith M., Kiebertz K., Corbett J., Feldon S., Friedman D., et al. The idiopathic intracranial hypertension treatment trial: clinical profile at baseline. *JAMA Neurol* .2014;71: 693–701.
26. Wall M. The headache profile of idiopathic intracranial hypertension. *Cephalgia*. 1990;10:331–335.
27. Dai Y, Jia N., Wang XL, Chen XH, Sun HL, Zhang XJ: Analysis of characteristics of ocular manifestations of benign intracranial hypertension. *Zhonghua Yan Ke Za Zhi*. 2010;46:1071-1074
28. Friedman DI: Papilledema and idiopathic intracranial hypertension. *Continuum* 2014;20:857-876
29. Matthew J. Thurtell, Michael Wall. Idiopathic Intracranial Hypertension (Pseudotumor Cerebri): Recognition, Treatment, and Ongoing Management. *Curr Treat Options Neurol*. 2013 Feb; 15(1): 1–12. doi: 10.1007/s11940-012-0207-4
30. Costa F, Neto FM, Gago G, Martins OG, Gibbon F, Nogueira LM. Pseudotumor cerebri presenting unilateral papilledema associated with iron-deficiency anemia. *Arq Bras Neurocir*. 2018;37:58-62
31. Thakkar DK, Patil A., Dolly Thakkar, Patil P., Jantre MN. Magnetic resonance imaging in pseudotumor cerebri: A case report. *Medical Journal of DY Patil University*. 2014.;7 (6):802-805
32. Ball AK, Howman A, Wheatley K, et al. A randomised controlled trial of treatment for idiopathic intracranial hypertension. *J Neurol*. 2011;258:874–881.
33. Liu GT, Kay MD, Bienfang DC, Schatz NJ. Pseudotumor cerebri associated with corticosteroid withdrawal in inflammatory bowel disease. *Am J Ophthalmol*. 1994;117:352–7.
34. Neville BG, Wilson J. Benign intracranial hypertension following corticosteroids withdrawal in childhood. *BMJ*. 1970;3(5722):554-556
35. De Simone R, Marano E, Fiorillo C, et al. Sudden re-opening of collapsed transverse sinuses and longstanding clinical remission after a single lumbar puncture in a case of idiopathic intracranial hypertension: pathogenetic implications. *Neurol Sci*. 2005;25:342–4.
36. Bulboaca AE, Angelo Bulboaca, Ioana Stanescu, Paul-Mihai Boarescu, Ioana Chirilă, Alexandra Bulboaca, Gabriela Dogaru Homonymous hemianopsia versus unilateral spatial neglect rehabilitation strategies in stroke patients, *Balneo Research Journal*. 2019;10(2):67–73 DOI 10.12680/balneo.2019.242.
37. Rosca C, Munteanu M, Tamasoi I, Petrovic Z, Balica N, Nicula C, Cretu O. Calcification of hydrophilic acrylic intraocular lens in eyes with silicone oil tamponade - an interventional case series report. *Acta Ophthalmol*. 2016 Sep;94(6):625-7. doi: 10.1111/aos.12887. Epub 2015 Oct 28.
38. Nicula C, Nicula D, Popescu R, Saplonțai-Pop A. Corneal collagen cross-linking in keratoconus -- long-term prospective study. *J Fr Ophtalmol*. 2015 Mar;38(3):199-205. doi: 10.1016/j.jfo.2014.10.007. Epub 2015 Feb 11.