

FILIP Roman Corina<sup>1,2</sup>, CATANĂ Maria-Gabriela<sup>1</sup>

Corresponding author: Corina Roman-Filip – Email: [corinaromanf@yahoo.com](mailto:corinaromanf@yahoo.com)



<sup>1</sup> Emergency Clinical Hospital Sibiu, Department of Neurology, Romania

<sup>2</sup> "Lucian Blaga" University, Sibiu, Romania.

## Abstract

The purely spinal form of multiple sclerosis, presenting as a progressive spastic paraparesis, hemiparesis, or, spastic monoparesis of a leg with varying degrees of posterior column involvement, is a special source of diagnostic difficulty. We present the case of a 47 years old patient, with no personal pathological antecedents, admitted in our department through the emergency ward for motor deficit of the lower limbs, symphomatology that had an acute onset the day before admittance. The neurologic examination revealed: orthostatism and gait not possible, spastic paraparesis – 3/5 MRC (medical research council), deep tendon reflexes were found to be hyperactive on both lower extremities, bilateral plantar extension, a dermatomic level of sensory disturbance at T10 – T11 vertebral segment and urinary retention. The cerebral MRI revealed no pathological findings. The lumbar puncture revealed oligoclonal bands and the spine MRI outlined multiple focal images with demyelination aspect reaching the cervical and dorsal level of the medullary cord. The patient had two more relapses each at approximately 6 months, and this allowed us to establish the final diagnostic: Pure spinal multiple sclerosis.

**Key words:** *spinal multiple sclerosis, paraparesis, neurorehabilitation,*

## Introduction

The purely spinal form of multiple sclerosis, presenting as a progressive spastic paraparesis, hemiparesis, or, spastic monoparesis of a leg with varying degrees of posterior column involvement, is a special source of diagnostic difficulty. Such patients require careful evaluation for the presence of spinal cord compression from neoplasm or cervical spondylosis. The diagnosis of multiple sclerosis is based on neurological signs and symptoms, alongside evidence of dissemination of CNS lesions in space and time. MRI is often sufficient to confirm the diagnosis when characteristic lesions accompany a typical clinical syndrome, but in some patients, further supportive information is obtained from cerebrospinal fluid examination and neurophysiological testing (1). Multiple sclerosis (MS) it is thought to be a complex disease, and poorly understood with regards to aetiology. Observational research has suggested genetic and environment influences through an underlined pathophysiology widely believed to be autoimmune in nature. The spinal cord is a critical structure and its damage can lead to dysfunction of motor and/or sensory systems, as occurs in cases of various musculoskeletal and neurodegenerative

diseases such as degenerative disc disease and multiple sclerosis. Spinal cord lesions on MRI correspond to areas of demyelination, neuroaxonal loss and gliosis, affecting spinal cord structure and function. Postmortem spinal cord studies have described a larger proportion of demyelination in the grey matter (33%) than in the white matter (20%), with lesions involving either both grey matter and white matter, or grey matter isolately. No difference in the extent of grey matter demyelination was seen between different cord levels (2).

## Case report

We present the case of a 47 years old patient, with no personal pathological antecedents, admitted in our department through the emergency ward for motor deficit of the lower limbs, symphomatology that had an acute onset the day before admittance. At admission blood pressure and heart rate were in normal range. No fever and no other abnormalities were found in the general examination. The neurologic examination revealed: orthostatism and gait not possible, spastic paraparesis – 3/5 MRC (medical research council), deep tendon reflexes

were found to be hyperactive on both lower extremities, bilateral plantar extension, a dermatomic level of sensory disturbance at T10 – T11 vertebral segment and dysfunction of the urinary bladder – urinary retention. The differential diagnosis included: myelitis, neuromyelitis optica, motor neuron disorders, vascular diseases and nutritional deficiencies. A presumptive diagnosis of multiple sclerosis has been outlined too, therefore further investigations have been made. Biological it was emphasized a mild hepatocytolysis, vitamin B12, folic acid, complete blood count, ionogram were in normal ranges.

The cerebral MRI revealed no pathological findings. A MRI of the thoracic spine and a lumbar puncture were performed. The lumbar puncture revealed oligoclonal bands and the spine MRI outlined multiple focal images with demyelination aspect reaching the cervical and dorsal level of the medullary cord, some of them gadolinophilic (active), that were less than 2 vertebral bodies in length (this also helped us to exclude Neuromyelitis Optica). We excluded all the above mentioned with the spine MRI, the lumbar puncture and, of course, the clinical exam. Neuromyelitis optica was excluded by negative aquaporin 4 antibodies and negative anti MOG antibodies.

There are new studies that discuss the effect of plasmapheresis in MS patients, but it should be taken into account that patients can develop multiple adverse effects, for example hypotension, tachycardia and severe allergies (3). Our patient responded to treatment with methylprednisolone (1g/day, for 5 days).

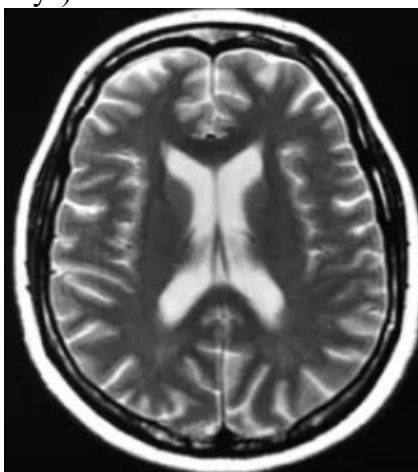


Fig. 1 .– Cerebral MRI (axial T2 sequence) – with no pathological findings

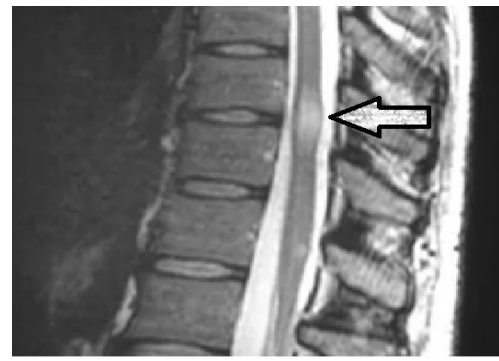

Fig. 2 .– Spinal MRI (sagittal T2 flair sequence) – focal image with demyelination aspect reaching the dorsal level (T10-T11) of the medullary cord.

The patient was tested for Hepatitis B and C, and she was positive for hepatitis B (agHBs positive). She received a recommendation to see a gastroenterologist and to make further investigation. After this admittance, the patient had two more relapses each at approximately 6 months. During this time the patient received treatment with Baclofen 10 mg 2 tablets/day for the spasticity. For the urinary retention, the patient learned to catheterize herself. Of course she started physiotherapy – kinetherapy. Because of Hepatitis B diagnosis we did not start any interferon or other immunosuppressive treatment. All in all, all these gathered together, allowed us to establish the final diagnostic: Pure spinal multiple sclerosis.

### Discussions

Motor symptoms are common and disabling across the phases and forms of multiple sclerosis (MS). Disease modifying treatments help to prevent their development, but most of their management is through rehabilitation. Current rehabilitation approaches are based on physical therapy focused on the individual's needs (1). The efficacy of these approaches, however, is limited, as it is purely based on clinical grounds, and is largely unpredictable in the individual case, where several factors, including location, extent, and severity of MS damage, can contribute to individual variation in rehabilitation outcomes (4).

Therefore, an improved understanding of the neural processes underlying functional recovery and driven by rehabilitation, remain a clinical necessity and a research priority that should fully exploit the individual patient's potential to recover motor function (5).

The complexity of the disease, the difficulty in determining the appropriate treatment and a wide range of symptoms call for a comprehensive approach to the patient, which would involve both pharmacology and neurorehabilitation. Our patient definitely needed physiotherapy, which is an integral part of rehabilitation and consists in kinesitherapy, physical therapy and massage (6).

Generally speaking and, even more, in this case, physiotherapy is aimed at improving mobility through compensation mechanisms that involve the activation of capabilities of effectors, which results in the patient regaining functioning, not movement. All applications included in physiotherapy should be recommended in such a way as to act upon the largest possible number of motor deficits. The introduction of physical activity, regardless of the severity of the disease, will reduce the negative effects of akinesia, and thus increase the functional capabilities of all body systems (7).

Patients with MS can develop in time, especially if there are cerebral lesions, problems with balance and coordination, so the inclusion of balance and coordination exercises into the therapy is necessary. Coordination and balance exercises are carried out according to the Frenkel method, in which footprints painted on the floor are used to learn proper gait. The exercises are performed in 3 phases (right foot steps forward, shift weight, left foot joins the right one). The movement is divided into three phases (feet withdrawn, forward leaning of the trunk, straightening of the legs and getting up) (8,9).

Spasticity was one of the main symptoms of our patient and is one of the symptoms that often makes rehabilitation and care difficult and most importantly deepens the disability. Spastic paresis affects both lower and upper limbs with greater severity of pathological tension in the lower extremities. Our patient had a spastic paraparesis which made walking very difficult. It is a symptom of the impairment of upper motor neuron which reveals excessive activity of alpha cells of the anterior horn of the spinal cord. High degree of spasticity (3 or 4 in Ashworth scale) causes contractures, joint deformities and bedsores which lead to infections (10). Sometimes spasticity from Multiple Sclerosis or even Neuromyelitis Optica can be accompanied by painful spasms that are paroxysmal episodes lasting seconds or minutes, accompanied by intense

pain and tonic postures of the limbs. Ephaptic transmission between abnormal demyelinated tracts could explain the spasms. Recently, the presence of these manifestations seems to be associated to NMO rather than MS or idiopathic acute transverse myelitis, and we excluded both of these pathologies (11). Apart from pharmacotherapy, physiotherapy plays an important role in the cases of severe spasticity. The plan of the rehabilitation program should take into account the fact that the use of physical applications before kinesiotherapy has positive effects while greater physical efforts can increase muscle tension (7).

Passive stretching is a contraindication, as it reduces the excitability of the motor neurons and maintains elasticity properties of muscles and joints. Other physical methods used in the treatment of spasticity are electrotherapy and magnetic therapy (10).

Electrical stimulation of neuromuscular system (NMES), transcutaneous electrical nerve stimulation (TENS), Hufschmidt method and functional electrical stimulation (FES) are listed among the applications of electrotherapy. Electrical stimulation seems to be the best method because damage to Upper Motor Neuron does not alter the excitability of the muscles to electrical stimuli, so that the impaired bioelectrical function of muscles can be replaced. Studies have shown that both methods result in a reduction of muscle tension, which leads to a wider range of motion in the joints and improved gait efficiency (8).

Physical activity in patients with multiple sclerosis improves not only their physical capacity, but also their mood and attitude towards the exercises. Better cardiorespiratory efficiency has been proven to enhance the cerebrovascular function, which suggests that movement can also significantly improve the brain function in patients with multiple sclerosis. Aerobic training increases muscle strength of the lower limbs, which manifests itself in reducing spasticity without the risk of relapse or the symptoms of fatigue (8). Recent recommendations for patients with multiple sclerosis suggest performing physical activities 2–3 times per week at an intensity of 60–80% of maximum heart rate. The duration of the exercise should not exceed the initial period of 40 min. The intensity should increase gradually depending on the degree of disability (10, 12).

As far as the medical treatment is concerned, patients suffering from RRMS will begin their treatment with a first-line drug, fingolimod and dimethyl fumarate being the most active ones in this category, having the great advantage of the oral administration. IFNs and GA are somewhat less efficient, but they passed the test of time, showing a good safety profile, however most forms of multiple sclerosis are remissive and recurrent on the onset, and later they turn progressive, and no treatment has proven to be efficient, so far (13). If the cognitive impairment appears it should be differentiated from other forms of dementia like Alzheimer disease, for example, where p-tau /A $\beta$ 42 or t-tau/A $\beta$ 42 ratio is used, with a sensitivity of up to 92% and a specificity of up to 86%. The ratio between A $\beta$ 42 and p-tau is significantly lower in AD patients compared to those with vascular dementia. Research studies on the treatment for cognitive impairment in MS patients are ongoing (14).

### Conclusions

We have presented an atypical case of spinal multiple sclerosis, with late onset, in a 47 years old patient that had a good evolution receiving cortisonic treatment in the acute phase, followed by treatment with central antispastics and kynetotherapy.

### Conflict of interest

No conflict of interest for any of the authors regarding this paper.

### Informed consent

An informed consent was obtained from the patient included in this article

### References

1. A. Hardy, Prof Franz Fazekas, Prof David H, Miller F, Diagnosis of multiple sclerosis: progress and challenges. *The Lancet*, VOLUME 389, ISSUE 10076, 2016, P1336-1346.
2. Lublin FD Reingold SC Cohen JA et al. Defining the clinical course of multiple sclerosis: the 2013 revisions. *Neurology*. 2014; 83: 278-286.
3. Sava Mihai, Catană Maria-Gabriela, Roman Corina, The importance of early neurorehabilitation in the recovery of post-vaccination Guillain-Barre syndrome – a case report. *Balneo Research Journal*. 2019;10(2):98–102 . 10.12680/balneo.2019.246.
4. Sombekke MH Wattjes MP Balk LJ et al. Spinal cord lesions in patients with clinically isolated syndrome: a powerful tool in diagnosis and prognosis. *Neurology*. 2013; 80: 69-75.
5. Wallner-Blazek M Rovira A Fillipp M et al. Atypical idiopathic inflammatory demyelinating lesions: prognostic implications and relation to multiple sclerosis. *J Neurol.* 2013; 260: 2016-2022.
6. Kwolek A, Podgórska J, Rykała J. Own experience in the rehabilitation of multiple sclerosis patients. *Przegląd Medyczny Uniwersytetu Rzeszowskiego*. 2010;2:213–220.
7. Steiborn B, Łuczak-Piechowiak A. Kinesytherapeutic methods in the treatment of spasticity. *Polski Przegląd Nauk o Zdrowiu*. 2006;1:95–103.
8. Miller L, Mattison P, Paul L, Wood L. The effects of transcutaneous electrical nerve stimulation (TENS) on spasticity in multiple sclerosis. *Mult Scler*. 2007;13:527–533.
9. Frago YD, Santana DLB, Pinto RC. The positive effects of a physical activity program for multiple sclerosis patients with fatigue. *Neurorehabilitation*. 2008;23:153–157.
10. Dalgas U, Ingemann-Hansen T, Stenager E. Physical exercise and MS. Recommendations *Int MS J*. 2009;16:5–11.
11. Corina Roman-Filip, A. Ungureanu, M. Cernusca Mitariu, "Paniful tonic spasms and brainstem involvement in a patient with neuromyelitis optica spectrum disorders" *Polish Journal of Neurology and Neurosurgery*, ISSN 0028-3843, Vol.50. Nr.1 pag.55-58, 2016
12. Sandroff BM, Dlugnski D, Weikert M, et al. Physical activity and multiple sclerosis: New insights regarding inactivity. *Acta Neurol Scand.* 2012;126:256–262.
13. Carmen Adella Sirbu, Emilia Furdu-Lungut, Cristina Florentina Plesa, Alina Crenguța Nicolae, Cristina Manuela Dragoi. Pharmacological treatment of relapsing remitting multiple sclerosis-where are we?. *Farmacia.* 2016, Vol. 64, 5.