

Case presentation

Clinical and rehabilitative considerations in a complex case of spastic tetraplegia, mixed aphasia, secondary encephalopathy – post severe traumatic brain injury with hemorrhagic and ischemic lesions – with favorable late evolution and post-symptomatic status after SARS-COV-2 infection

Ruxandra Luciana Postoiu ², Elena-Madalina Mocanu ², Simona Schek ², Magdalena Lapadat ², Carmen Elena Chipăruș ², and Gelu Onose ^{1,2}

¹ „Carol Davila” University of Medicine and Pharmacy, Bucharest, Romania

² Teaching Emergency Hospital „Bagdasar Arseni” (THEBA) Bucharest, Romania

Correspondence: Ruxandra Luciana Postoiu, postoiu.ruxandra@yahoo.ro

Citation: Postoiu et al., Clinical particularities regarding rehabilitation treatment of a young patient with right pontine ischemic stroke, resulting in dysarthria and left side brachial and crural hemiparesis, and quite recent COVID-19 history.

Balneo and PRM Research Journal 2022, 13(1): 485.

Academic Editor(s):
Constantin Munteanu

Reviewers:
Sinziana Călina Silișteanu
Simona Pop

Received: 15.02.2022
Accepted: 18.03.2022
Published: 21.03.2022

Publisher's Note: Balneo and PRM Research Journal stays neutral with regard to jurisdictional claims in published maps and institutional affiliations.



Copyright: © 2022 by the authors. Submitted for possible open access publication under the terms and conditions of the Creative Commons Attribution (CC BY) license (<https://creativecommons.org/licenses/by/4.0/>).

ABSTRACT: The traumatic brain injury remains a current research topic considering the severity and the increased incidence of this pathology. Both physical and neuro-psychological sequelae require a complex rehabilitation program. **Material and methods.** We describe the evolution of a 20-year-old case, victim of a severe traumatic brain injury due to physical aggression, with spastic tetraplegia, extended ischemia in the left cerebral hemisphere, mixed aphasia, post-traumatic encephalopathy, left eyelid ptosis, right paresis of nerve III, post remitted status of left subdural hematoma, post remitted status of right fronto-parietal subarachnoid hemorrhage, severe joint stiffness (right elbow and fist, bilateral hips and knees), cachexia and SARS-COV-2 infection. In our clinic the patient followed medical, complex kinetherapeutic treatments and was functionally assessed using the following scales: modified Ashworth, Penn Spasm Frequency Scale (Penn), Life Quality Assessment (QOL), Montreal Cognitive Assessment (MoCA), FAC International Scale, Glasgow Outcome Scale-Extended (GOS-E), modified Rankin scale (mRS). **Results.** During the hospitalization, the patient presented a favorable late evolution with a great improvement of motor and neurological deficit, aphasia in remission, improvement of eyelid ptosis and joint stiffness, fact also confirmed by the increasing scores from the evaluated scales. **Conclusions.** Consequently in traumatic brain injury the proper medication, personalized rehabilitation program, ergotherapy, speech therapy, a great deal of involvement and documentation of current information is required to improve the patient's quality of life.

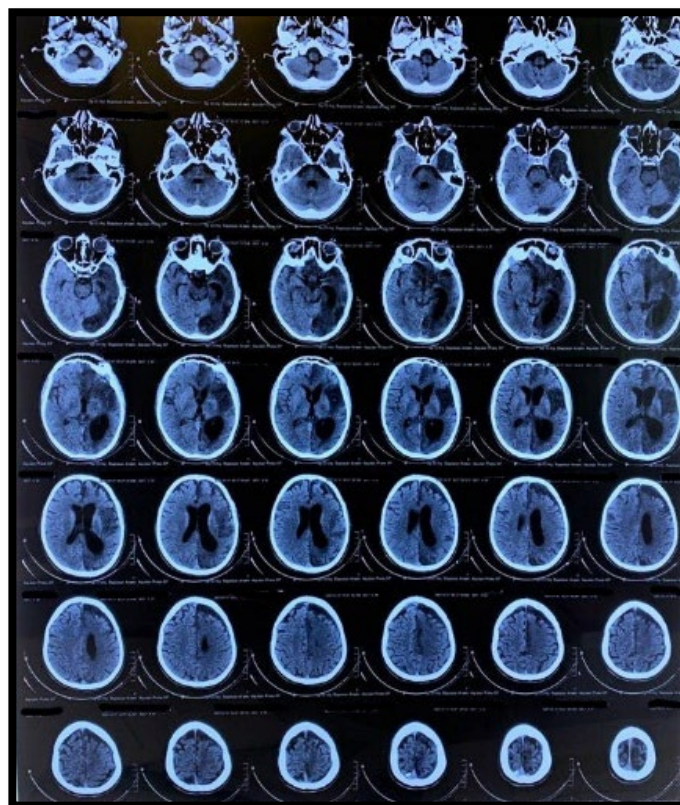
Keywords: *traumatic brain injury, neuro-rehabilitation program, spastic tetraplegia*

1. INTRODUCTION

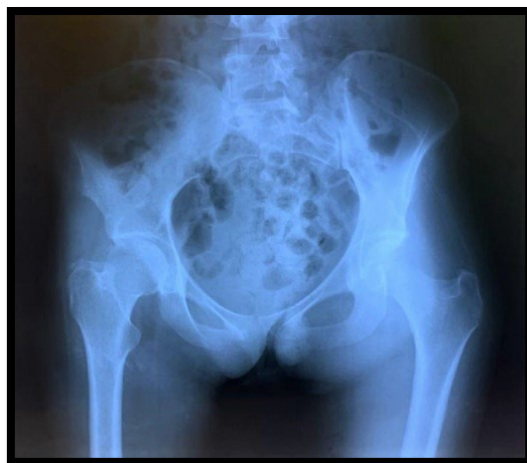Traumatic brain injury (TBI) stands as a major public health problem and one of the most important challenges for neurological rehabilitation, (1) it requires dramatic, heroic therapeutic measures in the acute phase; involves complex, long-term, sophisticated and expensive medical recovery programs in the subacute and chronic phases (2) Aggression is one of the most common consequences of traumatic brain injury (TBI) (3). The intensity of the recovery treatment is individually adapted (4) Recovery phase involves gaining as much independence as possible, improving the quality of life so that the patient can be reintegrated into society (5-11).

Materials and Methods: This paper presents the case of a 20-years-old patient, victim of a physical aggression in November 2020 with severe traumatic brain injury, brought to a territory hospital with a serious, comatose general condition GCS=6 and spastic tetraplegia. Dragging evolution in ICU with prolonged febrile syndrome, inflammatory syndrome, infectious syndrome, sinus tachycardia. Dynamic brain CT showed the withdrawal of subdural hematoma and subarachnoid hemorrhage but the maintenance of ischemia in the left hemisphere. Carotid doppler examination ruled out carotid lesions (carotid dissection). Then she transferred to the neurology department. The patient is initially fed on the gastrostoma, later the swallowing disorders are alleviated and the gastrostoma is suppressed. It was necessary to mount orthoses at the right elbow and right tibiotarsal joint. Motor deficit such as spastic tetraplegia is maintained but also important, painful joint stiffness that prevents the patient's mobilization. In March 2021 she was hospitalized at TEHBA Neurosurgery IV where the case was considered to have no neurosurgical indication, then transferring to our Neuro-Muscular Recovery department. At admission, at the clinical examination, the patient had a mediocre general condition, cachexia, pale, dry skin and mucous membranes, bilateral calcaneus ulcers grade I-II, postoperative scar right hypochondrium, excavated chest, SpO2=96% spontaneous; BP=110/60 mmHg; HR= 125 bpm rhythmic; important joint stiffness at the level of right upper limb: elbow joint 85 degrees, fist 105 degrees; and of right lower limb: knee 60 degrees; controlled micturition in adult diapers. Neurological examination: conscious patient; disoriented temporally, spatially and in person; answers monosyllabically to questions, not always correct, answers frequently " I don't know"; psychoemotional lability with phenomena of negativity (refusal to eat, refusal to mobilize limbs on command); paresis of left nerve III; right anisocoria>left anisocoria; spastic tetraplegia with predominance of right hemiplegia; apparent hyperpathy without objective sensivity disorders; significant amyotrophy in all limbs. Paraclinical examinations and interdisciplinary consults: CT in dynamics showed relief of hemorrhagic lesions, but maintaining the area of extensive ischemia of the left cerebral hemisphere.

Carotid doppler examination ruled out carotid traumatic lesions that explain ischemia. Cardiac Ultrasound ruled out the presence of intracavitary thrombi.



Radiography of the pelvic joint showed demineralization of bone segments, discrete narrowing of the bilateral coxo-femoral joint space and bone productions in the vicinity of the great trochanter and of the posterior acetabular contour on the right side.



Clinical diagnosis : Spastic tetraplegia with predominance of right hemiplegia, mixed aphasia, deteriorating psychoorganic syndrome, paresis of left nerve III, all in remission, post severe TBI in a polytraumatic context (aggression) with left subdural hematoma and right fronto-parietal subarachnoid hemorrhage, left cerebral ischemia, sinus tachycardia in treatment, cachexia, severe joint stiffness right elbow and fist, bilateral hip and knee, post SARS-COV-2 infections status.

The neuro-muscular rehabilitation program:

The objectives of the recovery program:

1. Improving the quality of live
2. Posture correction
3. Recovery of locomotive capacity as much as possible
4. Improving the capacity for coordination, control and balance

| RESULTS BASED ON HOSPITALIZATION SCALES AND AFTER THE RECOVERY PROGRAM | | |
|---|---|--|
| BEFORE RECOVERY PROGRAM | AFTER RECOVERY PROGRAM | EVOLUTION |
| mAshworth = 4 | mAshworth = 3 | mAshworth = -1 |
| Penn | Penn | Penn |
| L UP = 2 R UP = 4 | L UP = 1 R UP = 2 | L UP = -1 R UP = -2 |
| L LL = 2 R LL = 4 | L LL = 1 R LL = 2 | L LL = -1 R LL = -2 |
| QOL = 28 / 112 | QOL = 61 / 112 | QOL = + 33 |
| MoCA = 2 / 30 | MoCA = 16 / 30 | MoCA = + 14 |
| FAC = 0 | FAC = 0 | FAC = 0 |
| GOS-E = 3 | GOS-E = 3 | GOS-E = 3 |
| Modified Rankin scale (Mrs) = 5 | Modified Rankin scale (Mrs) = 4 | Modified Rankin scale (Mrs) = -1 |

5. Improving joint mobility, endurance and muscle strenght
6. Reintegration into society

The patient underwent medication treatment with injectable anticoagulant, brain trophic, decotracting, B and C vitamins, iron preparations, symptoms, hydro-electrolytic rebalancing, physical therapy (kinesiotherapy), speech therapy and psychotherapy. The patient followed an individualized medical recovery program. Initially it was achieved with great difficulty due to the patient's physical and mental condition. Subsequently was performed : passive, passive-active and active joint gymnastics of the upper and lower limbs at the patient's bed; progressively mobilized with the bed, at the edge of the bed with help; progressive mobilization in a wheelchair and performing exercises at the physiotherapy

room: for the lower limbs exercises with movable plate, pedalboard; for the upper limbs exercises with dumbbells and in the end verticalization at the trellis.

Results and discussion: Slow favorable evolution, the patient during hospitalization: conscious, more cooperative, with a slight improvement of the motor deficit, with the persistence of joint stiffness in the right lower and upper limbs, with good tolerance in a wheelchair, with gradual increase in range of motion, with increased tolerance to pain, with obvious improvement in speech disorders and psycho-emotional lability. During the hospitalization the patient was diagnosed with SARS COV-2 positive and she was being hospitalized in a covid support hospital with a medium form.

As complications, due to the prolonged immobilization in decubitus, the above-mentioned joint stiffness appeared with a slowly favorable evolution through kinesiotherapy but with the need for orthopedic evaluation and necessity treatment.

The case presented being a polytrauma through aggression implies neurological, orthopedic and psychoemotional involvement.

As a particularity of the case we mention the presence and necessity of the recovery treatment of both hemorrhagic and ischemic lesions at the cerebral level. If hemorrhagic lesions have resolved with conservative treatment, the extensive ischemic lesion of the cerebral hemisphere still requires medical treatment and monitoring as well as physical therapy and speech therapy.

Conclusion: In conclusion, the presented case had an undulating evolution specific to severe neurological lesions that required initial prolonged immobilization in bed, later compensated by the intense recovery program. This was possible only through teamwork, the collaboration of the patient and the belongings and with the multidisciplinary medical team.

Conflict of interest No conflict of interest declared.

This study has approval of the Ethics Commission of the Clinical Emergency Hospital "Bagdasar-Arseni" (N.O. 24389/28.06.2021)

References

1. Mazaux JM, Richer E. Rehabilitation after traumatic brain injury in adults. *Disabil Rehabil.* 1998 Dec;
2. Ghid de diagnostic/evaluare, principii terapeutice și neuroreabilitare în suferințe după traumatisme craniocerebrale. Prof. Univ. Dr.Gelu Onose, Ș.L.Dr. Aurelian Anghelescu.
3. Aggression After Traumatic Brain Injury: Prevalence and Correlates- Vani Rao M.D.Paul Rosenberg M.D.Melaine Bertrand M.P.H.Saeed Salehinia M.D.Jennifer Spiro M.S.Sandeep Vaishnavi M.D. – *The Journal of Neuropsychiatry and Clinical Neurosciences*
4. Reabilitarea medicala a bolnavului cu traumatism cranio-cerebral – Protocol clinic national, Chisinau 2018
5. Ionițe C., Arotăriței D, Turnea M., Ilea M., Rotariu M., Applications of fitness function in Pubalgia affliction, *Balneo and PRM Research Journal.* 2021;12(1):77–81 Full Text DOI 10.12680/balneo.2021.423
6. Condurache I., Turnea M., Rotariu M., Improving functional and motor capacity through means/resources and methods specific to aquatic activities, *Balneo and PRM Research Journal.* 2021;12(1):27–30 Full Text DOI 10.12680/balneo.2021.414
7. Munteanu C., Rotariu M., Dogaru G., Ionescu E.V., Ciobanu V., Onose G., Mud therapy and rehabilitation - scientific relevance in the last six years (2015 – 2020) Systematic literature review and meta-analysis based on the PRISMA paradigm, *Balneo and PRM Research Journal.* 2021;12(1):1-15 Full Text DOI 10.12680/balneo.2021.411
8. Munteanu C., Dogaru G., Rotariu M., Onose G., Therapeutic gases used in balneotherapy and rehabilitation medicine - scientific relevance in the last ten years (2011 – 2020) - Synthetic literature review, *Balneo and PRM Research Journal.* 2021;12(2):111-122 Full Text DOI 10.12680/balneo.2021.430
9. Iordan D.A., Mocanu G.-D., Mocanu M.-D., Munteanu C., Constantin G.B., Onu I., Nechifor A., Age-Related, Sport-Specific Dysfunctions of the Shoulder and Pelvic Girdle in Athletes Table Tennis Players. Observational Study, *Balneo and PRM Research Journal.* 2021;12(4):337–344 Full Text DOI 10.12680/balneo.2021.461
10. Munteanu C., Munteanu D., Onose G., Hydrogen sulfide (H₂S) - therapeutic relevance in rehabilitation and balneotherapy Systematic literature review and meta-analysis based on the PRISMA paradigm, *Balneo and PRM Research Journal.* 2021;12(3):176-195 Full Text DOI 10.12680/balneo.2021.438
11. Munteanu C., Teoibaș-Șerban D., Iordache L., Balaurea M., Blendea C.-D., Water intake meets the Water from inside the human body – physiological, cultural, and health perspectives - Synthetic and Systematic literature review, *Balneo and PRM Research Journal.* 2021;12(3):196-209 Full Text DOI 10.12680/balneo.2021.439