

Research article

# Brain Mapping – Neuromuscular correlations in long-term Postsurgical rehabilitation of Adult Brachial Plexus Palsies

Dan Trofin<sup>1</sup>, Cristina Grosu<sup>2,3,†</sup>, Daniel Andrei Iordan<sup>4,5,\*</sup>, Daniela-Marilena Trofin<sup>3,†</sup>, Ilie Onu<sup>1,6,\*</sup>, Teodor Stamate<sup>2,7</sup>, Daniela-Viorelia Matei<sup>1</sup>

**Citation:** Trofin D., Grosu C., Iordan D.A., Trofin D.M., Onu I., Stamate T., Matei D.V. - Brain Mapping – Neuromuscular correlations in long-term Postsurgical rehabilitation of Adult Brachial Plexus Palsies *Balneo and PRM Research Journal* 2024, 15(1): 672

Academic Editor(s):  
Constantin Munteanu

Reviewer Officer:  
Viorela Bembea

Production Officer:  
Camil Filimon

Received: 26.02.2024  
Published: 31.03.2024

**Reviewers:**  
Roxana Bistriceanu  
Ioana Andone

**Publisher's Note:** Balneo and PRM Research Journal stays neutral with regard to jurisdictional claims in published maps and institutional affiliations.



**Copyright:** © 2023 by the authors. Submitted for possible open-access publication under the terms and conditions of the Creative Commons Attribution (CC BY) license (<https://creativecommons.org/licenses/by/4.0/>).

- 1 Department of Biomedical Sciences, Faculty of Medical Bioengineering, University of Medicine and Pharmacy "Grigore T. Popa" Iasi, 700454 Iasi, România; trofin.dan@umfiasi.ro (D.T.);
- 2 Faculty of Medicine, University of Medicine and Pharmacy "Grigore T. Popa" Iasi, 700454 Iasi, România; fcristina\_ro@yahoo.com;
- 3 Clinical Recovery Hospital Iasi, 700661 Iasi, Romania; dr.danielatrofin@gmail.com;
- 4 Department of Individual Sports and Physiotherapy, Faculty of Physical Education and Sport, "Dunarea de Jos" University of Galati, 800008 Galati, Romania;
- 5 Center of Physical Therapy and Rehabilitation, "Dunarea de Jos" University of Galati, 800008 Galati, Romania;
- 6 Department of Physiotherapy, Micromedica Clinic, 610119 Piatra Neamt, România;
- 7 Department of Plastic and Reconstructive Surgery, "Sf. Spiridon" Emergency Hospital, 700111 Iasi, România

\* Correspondence: ilie.onu@umfiasi.ro (I.O.), daniel.iordan@ugal.ro (D.A.I)

† This author contributed equally to this work with the first author

**Abstract:** Background: Correlations of Transcranial magnetic stimulation (TMS) mapping of the cortical area and electromyography (EMG) + dynamometric testing may demonstrate active neuroplasticity events that are reliant on rehabilitation therapy (RT) compliance in adult postsurgical brachial plexus (BP) injuries. Material and Methods: On the right (dominant) arm of two patients with chronic operated BP lesions, we evaluated the progress of functional recovery. The traumatic event was dated more than 10 years ago for both patients. The first patient (male, 50 years old) and the second one (female, 58 years old) had a history of several microsurgical neurotization and muscle transfer procedures, with less amelioration of the motor deficit, especially related to elbow flexion (MRC 1/5 and 2/5, respectively). We followed up their evolution by EMG parameters, dynamometry, MRC scaling, and TMS. The motor region of the limb was mapped using TMS to assess the amplitudes of the motor evoked potentials (MEP), on a 4-axis protocol. The patients were assessed twice, with the second examination performed after RT had just finished. TMS findings were compared with EMG and dynamometric results. Results: Higher MEP amplitudes were associated with improved MEP latency during stimulation of the left cerebral hemisphere's cortical area, as well as at the cervical level. EMG findings, both nerve conduction and needle EMG studies showed nonsignificant improvements, as well as muscle strength (as measured by the hydraulic dynamometer). The best results for the first patient showed an increase in MEP's amplitude increase from 1.08 mV to 1.49 mV (in the hotspot), which correlated with measurable latencies, as compared to the first TMS (when no response was obtained at cervical stimulation). The second patient also had improvements in latencies: from 37.1 msec. to 36.3 msec. (cervical stimulation with recording at bipital level) and from 39.2 msec. to 37.9 msec. (cervical stimulation recording at the first interosseous), with a hotspot increase from 1.35 mV to 1.98 mV. The results demonstrate cortical region reactivity in regard to therapeutic techniques. Central modifications do not correlate with visible EMG and dynamometric improvements. Patients with traumatic BP palsy may receive several microsurgical reconstructive procedures, nevertheless, the rehabilitation of the upper limb's functionality may sometimes still be limited. This increases the risk of discontinuity of the neuromotor RT. We aim to prove that in spite of little correlations with clinical and EMG findings, mapping the cortical area using TMS provides proof of ongoing neuroplasticity phenomena, dependent on adherence to RT. Conclusion: The evidence of continued brain activity supports the requirement for long-term adherence to treatment guidelines and long-term study protocols.

**Keywords:** brachial plexus; transcranial magnetic stimulation; brain mapping; rehabilitation

## Introduction

Adult brachial plexus (BP) palsies represent an important cause of disability, with complicated microsurgical reconstruction strategies. The potential of poor recovery outcomes negatively impacts the overall quality of life by the underlying negative influence upon motor cortical representation of the limb [1].

All of the physiopathological events that occur during the evolution of the brachial plexus (BP) lesions (starting with the first Wallerian degeneration signs in the proximal region of the affected nerve, up to the earliest signs of muscle atrophy) will eventually impact the sensory-motor representation of the affected limb among the cortical level [1,2].

Reconstructive surgery is essential in posttraumatic adult BP lesions. Neurotization (nerve transfer) is one of the most preferred surgical approaches, when possible. A good example is the Oberlin procedure, an ulnar nerve fascicle transferred to the musculocutaneous branch to the biceps brachii. Nevertheless, if the first surgical approach does not lead to satisfactory results, tendon transfers or even muscle transplantation can be applied [3]. Thus, a variety of musculotendinous transfers can be used to restore elbow flexion: the latissimus dorsi muscle to the biceps brachii tendon; the pectoralis major tendon (the brachial branch) to the biceps brachii muscle (Clark technique), or the transfer of the triceps tendon to the latissimus dorsi muscle (Steindler technique), as such examples [1,3].

Electromyography (EMG), including nerve conduction studies (motor and sensory), can assess nerve growth within the following weeks after the lesion occurred, either for the evaluation of natural recovery or to plan the surgical intervention [3]. However, in chronic patients, after years of motor deficit, its utility can rely mostly on the impact of rehabilitation, in compliant patients, usually with modest to no signs of improvement [4,5].

The principle of Transcranial Magnetic Stimulation (TMS) consists of sending a magnetic impulse to a specific brain area and recording its effect. Depending on the stimulated area, the method can provide a wide range of information. Stimulation of the motor area allows the electromyographic recording of the motor response by generating evoked potentials. Stimulation along predetermined axes centered on the point of the greatest motor evoked potential (MEP), the hotspot, allows the drawing of cortical motor maps [7,8].

The basic principle of TMS brain mapping is the realization of a map of specific body segmental projections. The number of motor cortex locations where MEP is produced in response to stimulation determines the charting. In most cases, the standardized stimulus applied should exceed the minimal amount required to produce MEP [7]. To record numerous MEP with variable amplitudes, the coil is moved above the surface of the skull on different axis systems, often from centimeter to centimeter. This produces a potential map by adding the varying amplitudes. The motor area's center is where the maximal amplitude is found, and it decreases as one moves toward the periphery [7,8]. The location where the maximum amplitude was recorded is considered to be the ideal point of the recording (the hotspot). The number of neurons involved in a specific contractile function decreases as we move toward the periphery. The impulses are sent towards the anterior horns of the spinal cord by the cortical neurons that make up the corticospinal tract. Moreover, the impulse travels to the muscle via the peripheral motor neuron. Hence, by analyzing the hotspot's position as well as the surrounding amplitudes of the MEPs, an electrophysiological pattern is finally represented [7,9].

Understanding the way that long-term rehabilitation procedures (under the influence of treatment protocol adherence) modify ongoing electric impulses within the motor cortex of two chronic patients, is relevant to our understanding of how cerebral plasticity is controlled in adult traumatic brachial plexus lesions.

The purpose of the study is to assess the utility of long-term medical rehabilitation protocols especially based on Neuro Muscular Electric Stimulation (NMES) and Proprioceptive Neuromuscular Facilitation (PNF) in maintaining ongoing cortical plasticity phenomena. By interpreting the motor deficiency and its effects long after the trauma occurs from the standpoint of concepts of cortical reactivity, the work that is being presented is novel.

## 2. Materials and Methods

We monitored the two patients with chronic BP palsies, that have received several reconstructive and palliative surgeries over the years.

The male patient in our first case represents a complex and entire affection of the BP, with elongation in the superior plexus and avulsions in the inferior region, following a traumatic event involving a fall from a height. At the time of our initial evaluation, the patient was 44 years old, and the injury happened when she was 31 years old.

His clinical presentation, which included a specific attitude of a fallen shoulder, was consistent from the start with the nerve conduction exam: no electrophysiological response in the radial, median, and ulnar nerves up to Erb's point and axillary level. Over the years, all surgical treatments have been doubled by ongoing rehabilitation, typically twice a year in various rehabilitation institutes. He was able to mildly abduct his arm with distinct finger flexion, particularly following Prof. Dr. Stamate's intervention in Iași to transfer the latissimus dorsi to the biceps brachii tendon. After a complex history of operations, the majority of which were palliative and carried out in various clinics around the nation, this remains the best surgical outcome. At the finger level, the hypotonia and paresthesia (up to dysesthesia) lasted for a considerable amount of time.

Over time, repeated EMG examinations have shown little improvement in the nervous conduction parameters, particularly in the sensory responses of the three nerves indicated. Additionally, the motor conduction velocity and compound muscle action potential (CMAP) amplitude in the median and radial nerves have also somewhat improved. Still, no axillary quantifiable CMAP was detected. All muscle regions displayed a chronic neurogenic pattern during the needle EMG evaluation, with the right deltoid muscle displaying full denervation signals.

Throughout the patient's medical history, additional interventions were required, including right fist arthrodesis, flexor carpi radialis transposition to the dorsal side, tenorrhaphy to the extensor tendons of the common group of fingers II–IV, transposition to the anterior of the extensor pollicis longus, and tenorrhaphy to the palmaris longus. In a palliative effort to restore the thumb's opposition, a late surgical procedure involved transposing the tendon of the fourth toe extensor to the tendon of the flexor carpi ulnaris.

A woman who was struck and dragged in an automobile accident 17 years ago is the representative of the second case. She also profited from several surgical treatments, the most notable of which was the Carrol procedure, which Prof. Dr. Stamate performed in Iași and produced long-lasting results (transposition of triceps brachii tendon to the distal insertion of the biceps brachii).

Over the years, EMG investigations have also been carried out; these have demonstrated a lack of electrophysiologic response from the first assessments for each of the three primary nerves, as well as modest improvements after various surgical procedures. Despite having a persistent restriction on elbow flexion, she gained from multiple rehabilitation programs, particularly in terms of her arm's abduction, laterality movements, and anterior projection (the finest motor performance to date).

The patients were evaluated before initiation of rehabilitation therapy protocol (physiotherapy, NEMS, and PNF) and 6 months afterward. The second patient only attended 10 sessions of therapy at the start of the follow-up period, while the first patient, beyond the first 10 initial sessions, also continued therapy in a 3 times per week schedule, until the endpoint evaluation.

The MRC scale, a muscle dynamometric strength test, ENMG, and TMS analysis were used to evaluate these patients clinically.

Utilizing a Magstim Rapid® device (Magstim Co Ltd, Whitland, Dyfed, UK) with an "8" or "butterfly" shaped coil with a medium diameter of 7 cm and the capacity to produce a magnetic field as strong as 1.2 Tesla, we performed TMS.

Both the needle EMG and the nerve conduction investigations were conducted using a two-channel Neurosoft® EMG instrument.

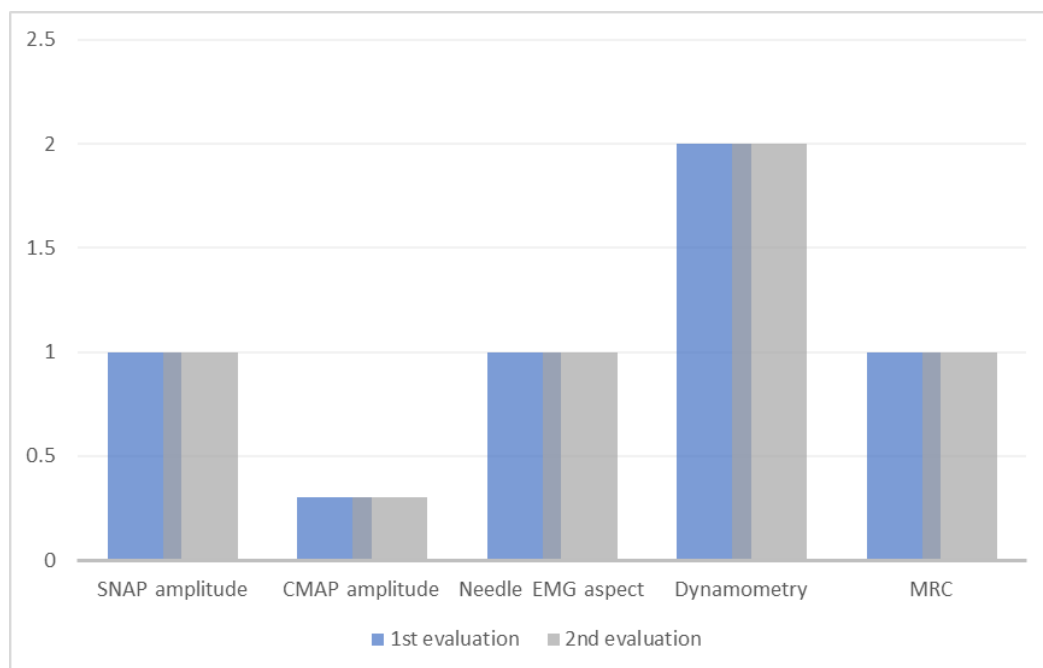
The hydraulic Jamar® dynamometer was used to carry out the dynamometric evaluation.

The Institutional Review Board, also known as the Ethics Committee of the University of Medicine and Pharmacy "Grigore T. Popa" Iași, under no. 13940/11.07.2019, gave its approval for the study, which was carried out by the Declaration of Helsinki's standards. In compliance with ethical guidelines, each patient provided written consent after being briefed about the study's protocol.

When performing TMS, besides analyzing parameters such as latency or the central motor conduction time (CMCT), we assessed the results on a 4-axis system translated to an Excel chart, by stimulating every 2 centimeters (as an adaptation to the technical particularities we had), above the motor area of the upper right limb (the left cerebral hemisphere, as both the patients were right-handed with affectation on the right). Through the use of this motor mapping technique, we were able to track the values' changes after rehabilitation.

### 3. Results

The parameters (dynamometric, MRC, SNAP and CMAP amplitudes, needle EMG patterns) remained unmodified at the 2 evaluations for the first patient (Figure 1).



**Figure 1.** Follow up of the first patient. SNAP – Sensory Nerve Action Potential (in relation to the value of 1  $\mu$ V amplitude); CMAP – Compound Muscle Action Potential (in relation to the value of 1 mV); needle EMG – using conventional value of 1 to describe the constant neurogenic aspect related to the morphology and the recruitment of the Motor Unit Potentials (MUP), with no signs of spontaneous pathological activity; Dynamometry – up to a maximum of 2 KgF; MRC – in this case, 1/5.

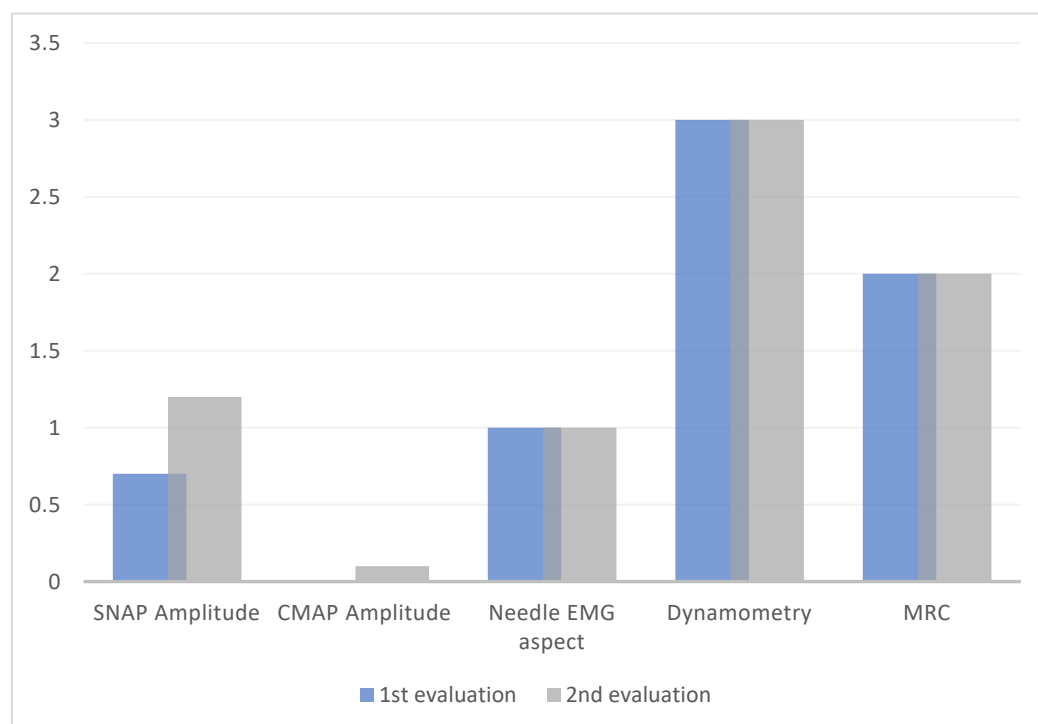
Six months after the first evaluation (after a session of physiotherapy NEMS, and PNF, continued 3 times weekly), CMCT decreased from 10 ms to 7.9 ms. The latency parameter is represented in Table 1.

Moment of evaluation	TMS					
	Cerebral		Cervical			
	Right	Left	Bicipital		FDI	
			Right	Left	Right	Left
	MEP latency (ms)	MEP latency (ms)	MEP latency (ms)	MEP latency (ms)	MEP latency (ms)	MEP latency (ms)
First evaluation	17	28	0	17,2	0	18
Second evaluation	17	26,9	35	17,2	39	19

**Table 1.** TMS follow-up of latency for the first patient.

Cerebral stimulus (recording at the First Digital Interosseous, FDI) and cervical stimulus (recording in both bicipital and FDI points)

The second patient, with only the initial therapy protocol, presented mild, insignificant amelioration of parameters, especially related to SNAP and CMAP amplitude, and the CMCT that improved from 11 ms (at the first evaluation) to 10.5 ms (at the second evaluation) (Figure 2 and Table 2).



**Figure 2** Follow-up of the second patient.

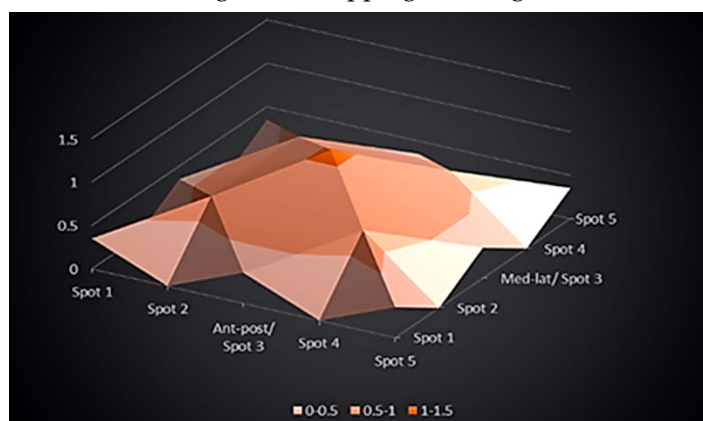
SNAP – Sensory Nerve Action Potential (in relation to the value of 1  $\mu$ V amplitude); CMAP – Compound Muscle Action Potential (in relation to the value of 1 mV); needle EMG – using conventional value of 1 to describe the constant neurogenic aspect related to the morphology and the recruitment of the Motor Unit Potentials (MUP), with no signs of spontaneous pathological activity; Dynamometry – up to a maximum of 3 KgF; MRC – in this case, 2/5.

Moment of evaluation	TMS					
	Cerebral		Cervical			
	Right	Left	Bicipital		FDI	
	MEP latency (ms)	MEP latency (ms)	Right MEP latency (ms)	Left MEP latency (ms)	Right MEP latency (ms)	Left MEP latency (ms)
First evaluation	17.3	27.6	37.1	16.2	39.2	16.6
Second evaluation	17.3	27.1	36.3	16.2	37.9	16.6

**Table 2.** TMS follow-up of latency for the second patient.

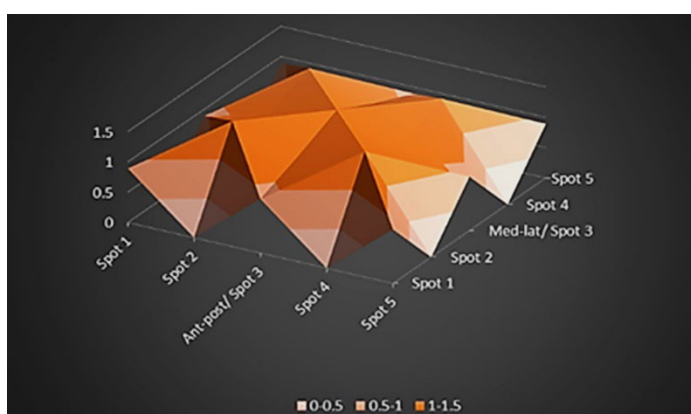
Cerebral stimulus (recording at the First Digital Interosseous, FDI) and cervical stimulus (recording in both bicipital and FDI points)

For the first patient, at the first evaluation, the values of the spots varied from a maximum of 1.08 mV at the hot spot, to 0.69 mV in peripheral regions, down to 0.35 mV in the farthest spots, hence resulting in the mapping from Figure 3.



**Figure 3.** First mapping of the motor area of the first patient, in an anteroposterior (ant-post) and medio-lateral (med-lat) axis system, at the left hemisphere level. The amplitude of the potentials is measured in mV.

During the second evaluation, the motor mapping was modified as in Figure 4.



**Figure 4** Second mapping of the motor area of the first patient.

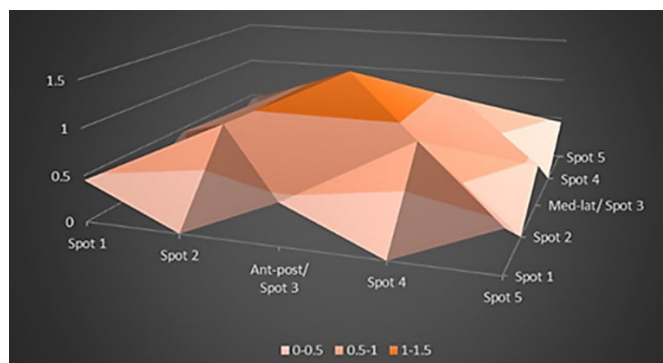
Ant-post: anteroposterior direction; med-lat: mediolateral direction. MEP’s amplitude is measured in mV.

In the control evaluation, MEP values ranged between 1.49 mV at the hotspot level, 1.17 mV nearby, and 0.89 mV within most peripheral stimulation spots. Considering the color code, where the most orange area represents the hotspot (well represented by the central point of the map, with its extension that can be seen in the control evaluation). The maximal MEP was also obtained in the proximity of the point where the MEP amplitude was maximal at the first examination, just as the immediately following value (0.89 mV) showed extension in the axis system, towards the periphery. Larger amplitudes of the MEP overlap, suggesting expansion.

This resulted in a more extensive map, in which there is no longer the notion of a peak as a central point associated with maximum amplitude, but rather a surface in the form of a plateau, representing a better activation of the motor cortical area, concurrent with the facilitation phenomenon.

These phenomena do not correlate with a visible or significant improvement in the other monitored parameters (neither in the EMG examination, nor in the MRC staging, nor the dynamometric assessment of muscle strength).

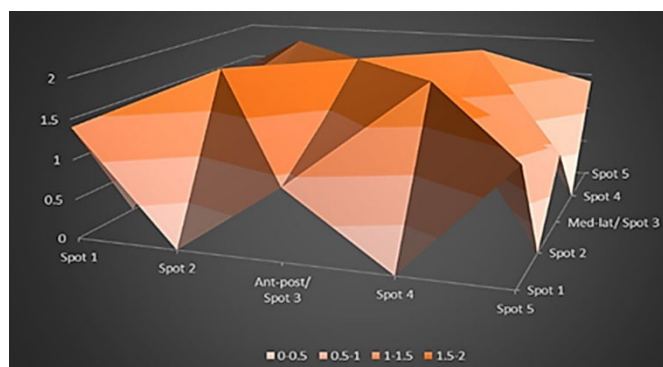
In the second case, the values of the MEP amplitude at the first examination, oscillate from a value of 1.35 mV at the level of the hot spot, to 0.89 mV in its proximity and 0.45 mV the most peripheral, resulting in the motor map in Figure 5.



**Figure 5.** Mapping of the motor area for the second patient, at the first evaluation.

Ant-post: anteroposterior direction; med-lat: mediolateral direction.  
MEP's amplitude is measured in mV.

At the next evaluation at the hotspot level, an amplitude of 1.98 mV was recorded, with extension in the vicinity, being followed by the maximum value of 1.4 mV, amplitude with extension towards the periphery of the area, where it is interspersed with values that decrease up to 0.9 mV (Figure 6).



**Figure 6** Mapping of the motor area, second patient, the second evaluation.

Ant-post: anteroposterior direction; med-lat: mediolateral direction.  
MEP's amplitude is measured in mV.

The representational dynamics at the cortical level correlate with better values of MEP latencies and are also reflected by the discrete improvement of the CMCT parameter in direct relation to the decrease of peripheral latencies, in both patients: from 10 ms to 7.9 ms (the first patient) and from 11 ms to 10.5 ms (second patient).

#### 4. Discussion

When there is a topographic pattern of persistent sensory-motor dysfunction in the brachial plexus, it may indicate either segmental demyelination or axonal disruption, perhaps both at different levels within the plexus. The number of axons injured determines how much muscle strength is lost, and discomfort and the loss of kinesthetic sensation frequently make the functional deficit worse. Some of the most perplexing patterns of motor, sensory, and vegetative interest can result from PB involvement. [10]. On clinical examination, the loss of motor functions, evidence of osteotendinous areflexia or sensory deficits may not always follow a very specific pattern of root or nerve trunk involvement [1,10,11].

Combined investigative methods, such as the one used by us in the present case, are at this time the only diagnostic options that can guide an accurate diagnosis, facilitating the opportunity for appropriate treatment. Based on our experience with our cases and current understanding, there is a direct correlation between muscular function and the EMG exam, and these two factors are linked to cortical representation. Although there are indications of decreased MEP latencies in TMS for the examined patients, the stationary aspect of the evaluated samples correlates between measurements made at different time intervals, suggesting implicitly that improved cortical activity is associated with improved medical recovery.

Where, due to the motor deficit, satisfactory facilitation cannot be achieved through muscle contraction, we appreciate the stimulation of cortical reactivity through a better propagation towards the activation of neighboring muscle areas, through nearby nerve branches, to generate MEP (sometimes even without significant movement of the limb).

We stimulated the primary motor region for the representation of the upper limb in these two patients to record TMS. In addition to using the butterfly-shaped coil to achieve optimum stimulation, we did so because we thought it would make it simpler to locate the hotspot. The triggered stimulus followed the path of the pyramidal way, through the corona radiata, through the internal capsule, at the level of the brain stem (bulbar junction), and then through the cervical spinal route. After the junction with the peripheral motor neuron, the impulse traversed the nerve path distally, towards the muscle, more difficult. Since patients were unable to adequately activate their muscles for optimal forearm flexion on the arm, we utilized the FDI muscle to help with the facilitation phenomena.

It is difficult to collect a statistically relevant number of cases for a certain type of neurotization, for a long-term follow-up, at least in the absence of an interdisciplinary territorial center, which brings together services of plastic and reconstructive surgery, neuromotor recovery, and functional explorations. This acts as a notable limitation in such interdisciplinary studies, along with the small sample size and inconsistent data related to the demographic status of the patients.

It should also be noted that this mapping exercise did not aim to highlight an already known correlation between the bicipital motor deficit and the cortical representation (which would have shown modestly), but from the perspective of the cortical adaptative modulation in PB lesions, following how later the different surgical procedures associated and sustained recuperative treatment, activate either reinnervation or complementary muscle groups. Therefore, the degree of cortical activation can be increased, this increase being compatible with the phenomenon of continuous neuroplasticity.



While peripheral latency is far more pertinent to the current study, we chose to closely examine it for the peripheral segment, even if CMCT is still an important measure in the diagnosis of various disorders of the central nervous system.

The patients' history is long, marked by many repair strategies, both surgical and rehabilitation-based. When the injury is chronic, and the muscle shows signs of atrophy, recovery can be viewed from the perspective of long-term psychomotor training. The methods used to stimulate the motor nerve component, which in turn stimulates the affected muscles, are the basis for the functioning of rehabilitation programs. These methods work in tandem with muscle fiber density to maintain a contractile potential, thereby preventing or stabilizing atrophy phenomena. Therapeutic strategies can also target the sensitive component, by training tactile discrimination, thus improving perceptual-motor coordination, restoring stereognosis, and implicitly reorganizing the representation of the affected segment of the body through maps at the cortical level [1,12,13,14].

Each muscle region may have several cortical projections that partially overlap due to the motor cortex's flexibility. A massive horizontal neural network facilitates communication across the various cortical areas simultaneously. Within the context of cerebral plasticity, it is believed that these specific horizontal connections may alter during the process of learning or healing, resulting in modifications at the motor map level. [15,16].

All these phenomena have a counterpart in the following cases and explain the expansion of the MEP amplitudes in the control mapping. The TMS results suggest a modest but present dynamic, an aspect that at this moment of chronic damage can only be explained by the impact generated by the continuity of the recuperative protocol over time.

The first patient appears to have a more pronounced motor and strength deficit, but the MEP amplitude values between the two patients are close. In this case, we believe the advantages of cortical dynamics can be explained by the patient's younger age (44 versus 58 years at the time of first presentation), which is a significant non-modifiable factor that needs to be considered in such studies [1,17,18].

The most complex part of the recovery of lost motor function is the reintegration of peripheral impulses at the cortical level, both from a sensory and motor point of view [19]. Without kinetic and sensory feedback from the effectors, a loss of cortical control center function may occur over time. The function of the affected limb will thus be less represented at the level of the cortex, in this context functional rehabilitation is mandatory after the microsurgical intervention on the peripheral nerve(s) [20,21,22]. The lost cortical functions will have to be relearned, as part of the redesign approach at the level of the sensory-motor homunculus [1,23]. Hence the need for lengthy rehabilitation procedures.

The TMS results point to the necessity of following long-term rehabilitation guidelines. Even though it is not always associated with improved functionality of the damaged limb, it might nevertheless be advantageous to the patient. The lack of a continuous and substantial correlation between the data points to the necessity for techniques that can be applied to broader patient populations, such as observational studies or larger clinical case series. Using TMS for motor mapping gives therapies targeted at enhancing psychomotor functions, especially idiomaticity as a functional meaning. Along the recovery process, interdisciplinarity is the common link in the collaboration between medical specialties: plastic and reconstructive microsurgery, clinical neurology, electrodiagnostic, and neuro-motor rehabilitation.

## 5. Conclusions

Prolonged neuromotor rehabilitation programs activate the cerebral mechanisms of representational plasticity of the damaged limb throughout time, even in the case of a recovery that does not result in significant clinical advantages. Since the data do not consistently and significantly correlate with one another, techniques that can be applied to larger patient populations, such as observational studies or extended clinical case series, are required.

Even while improved functionality of the damaged limb is not always correlated with a long-term recovery plan, it may still be advantageous for the patient. It is a potential idea to maintain these active areas with neuromotor rehabilitation therapies, notably in elbow flexion, even if long-term clinically significant results are not observed.

In addition to being novel in these ways, the research that is being presented also monitors the patient's adaptation to a rehabilitation program from the standpoint of compliance or non-compliance. This is assessed in light of age as well as non-modifiable aspects of plexus injuries, such as the degree of motor loss.

The primary conclusion drawn from examining the development of the two patients is that long-term patient adherence to a rigorous rehabilitation program enhances the cortical representation of the corporal segment, and this may be supplemented in the future with further clinically beneficial correlations.

The perspective that active mechanisms remain at the cortical level, even if the body segment represented at that level presents an important disability, is promising and encouraging for future innovations in medicine. Maintaining these active areas through neuromotor rehabilitation therapies, even if clinically significant results are not seen in the long term, particularly in elbow flexion, is a promising notion. Extended and more standardized research protocols would enable a more focused approach to this condition, from the standpoint of electrodiagnostic assessments and reconstructive microsurgery, as well as from the perspective of neuromotor rehabilitation, for improved multi and interdisciplinary approaches. Under these circumstances, at the very dawn of artificial intelligence, joining the current state of knowledge we consider to be beneficial.

**Author Contributions:** All authors have read and agreed to the published version of the manuscript.

**Funding:** This research received no external funding.

**Institutional Review Board Statement:** The study was conducted according to the guidelines of the Declaration of Helsinki and approved by the Institutional Review Board (or Ethics Committee) of the University of Medicine and Pharmacy "Grigore T. Popa" Iasi with no. 13940/11.07.2019.

**Informed Consent Statement:** Informed consent was obtained from all subjects involved in the study.

**Data Availability Statement:** Data are contained within the main text of the article.

**Acknowledgments:** All authors have equally contributed to this article as senior authors.

**Conflicts of Interest:** The authors declare no conflicts of interest.

## References

1. Stamate, T. Microchirurgia reconstructivă a nervilor periferici. *Iași, Tehnopress*, **1998**, 58-9, 67-70, 494-5, 498-508, 536, 542-6.
2. Lundborg, G. Brain plasticity and hand surgery: An overview. *J. Hand. Surg. Br.* **2000**, *25*, 242-252.
3. Al-Qattan, MM., Al-Kharfy, TM. Median nerve to biceps nerve transfer to restore elbow flexion in obstetric brachial plexus palsy. *Biomed Res Int.* **2014**, *854084*.
4. Lim, SH., Lee, JS., Kim, YH. et al. Spontaneous recovery of non-operated traumatic brachial plexus injury. *Eur J Trauma Emerg Surg.* **2018** *44*(3):443-449.
5. Mansukhani, KA. Electrodiagnosis in traumatic brachial plexus injury. *Ann Indian Acad Neurol.* **2013** *16*(1):19-25.
6. Kelly, BM., Leonard, JA. Rehabilitation concepts for adult brachial plexus injuries. *Practical Management of Pediatric and Adult Brachial Plexus Palsy*, Elsevier Saunders, **2012**, *21*, 301-317.
7. Lupescu, DT., Sirbu, CA., Constantin, D. Electromiografie. Potențiale evocate. *Edit. Univ. Carol Davila, București*, **2006**, 7-12, 17-26, 43-60, 74-6, 85-6, 94-101, 104-6.
8. Rossini, PM., Burke, D., Chen, R. et al. Non-invasive electrical and magnetic stimulation of the brain, spinal cord, roots and peripheral nerves: Basic principles and procedures for routine clinical and

- research application. An updated report from an I.F.C.N. Committee. *Clin Neurophysiol*, **2015**, *126*, 1071–1107.
9. Lacusta, V. Stimularea transcraniană directă cu curent continuu. Tratatament alternativ în Psihoneurologie. *Ghid pentru medici*. Chișinău, **2011**, 9–13.
  10. Daia, C. Examen local în recuperare. Ed. a II-a, revizuită. *Editura Universitară*, București, **2022**, 122–148, 233–242.
  11. Degenhart, AD., Hiremath, SV., Yangm Y. et al. Remapping cortical modulation for electrocortico-graphic brain-computer interfaces: a somatotopy-based approach in individuals with upper-limb paralysis. *J Neural Eng*. **2018**, *15*, (2):026021.
  12. Demondion, X., Herbinet, P., Boutry, N. et al. Sonographic mapping of the normal brachial plexus. *AJNR Am J Neuroradiol*. **2003**, *24*, (7):1303–9.
  13. Emamhadi, M., Andalib, S. Successful recovery of sensation loss in upper brachial plexus injuries. *Acta Neurochir (Wien)*. **2018**, *160*, (10):2019–2023.
  14. Feng, JT., Liu, HQ., Hua, XY. et al. Brain functional network abnormality extends beyond the sensorimotor network in brachial plexus injury patients. *Brain Imaging Behav*. **2016**, *10*, 4, 1198–1205.
  15. Navarro, X. Chapter 27: Neural plasticity after nerve injury and regeneration. *Int Rev Neurobiol*. **2009**, *87*:483–505.
  16. Hua, XY., Lim ZY., Xum WD. et al. Interhemispheric functional reorganization after cross nerve transfer: via cortical or subcortical connectivity? *Brain Res*. **2012**, *30*, 1471:93–101.
  17. Taylor, KS., Anastakis, DJ., Davis KD. Cutting your nerve changes your brain. *Brain*. **2009**, *132*(Pt 11):3122–33.
  18. Limthongthang, R., Bachoura, A., Songcharoen, P., Osterman, AL. Adult brachial plexus injury: evaluation and management. *Orthop Clin North Am*. **2013**, *44*(4):591–603.
  19. Li, T., Hua, XY., Zheng, MX. et al. Different cerebral plasticity of intrinsic and extrinsic hand muscles after peripheral neurotization in a patient with brachial plexus injury: A TMS and fMRI study. *Neurosci Lett*. **2015**, *14*:604:140–4.
  20. Malesy, MJ., Thomeerm RT., van Dijkm JG. Changing central nervous system control following intercostal nerve transfer. *J Neurosurg*. **1998**, *89*(4):568–74.
  21. Mano, Y., Chuma, T., Watanabe, I. Cortical reorganization in training. *J Electromyogr Kinesiol*. **2003**, *13*(1):57–62.
  22. Milicin, C., Sîrbu, E. A comparative study of rehabilitation therapy in traumatic upper limb peripheral nerve injuries. *Neuro Rehabilitation*. **2018**, *42*, 113–119.
  23. Simon, NG., Franz, CK., Gupta, N. et al. Central Adaptation following Brachial Plexus Injury. *World Neurosurg*. **2016**, *85*:325–32.

**Disclaimer/Publisher's Note:** The statements, opinions and data contained in all publications are solely those of the individual author(s) and contributor(s) and not of MDPI and/or the editor(s). MDPI and/or the editor(s) disclaim responsibility for any injury to people or property resulting from any ideas, methods, instructions or products referred to in the content.