

CEREBROSPINAL FLUID LEAK AFTER LUMBAR LAMINECTOMY-CLINICAL CASE

A.D. NEDELCU¹, M.G. ILIESCU^{1,2}, S. APOSTOL^{1,2}, A.B. UZUN^{1,2}, L.E. STANCIU^{1,2}

¹ Balneal and Rehabilitation Sanatorium Techirghiol, Romania, ² Ovidius University of Constanta, Faculty of Medicine, Constanta, Romania

INTRODUCTION: Laminectomy represents the partial or complete removal of the vertebral lamina in the context of a herniated disk. Cerebrospinal fluid leak is a complication of vertebral surgery, especially with lumbar localization.

MATERIALS & METHODS: Clinical case of a 43-year-old female patient who was admitted for intermittent lumbago. In personal history, the patient had a right L4-L5 disc herniation operated by partial hemilaminectomy, which developed a cerebrospinal fluid leak as an intraoperative complication. Initially, an attempt was made to repair the leak by using a dural substitute material. Within ten days, surgery was performed again by applying an epidural blood patch.

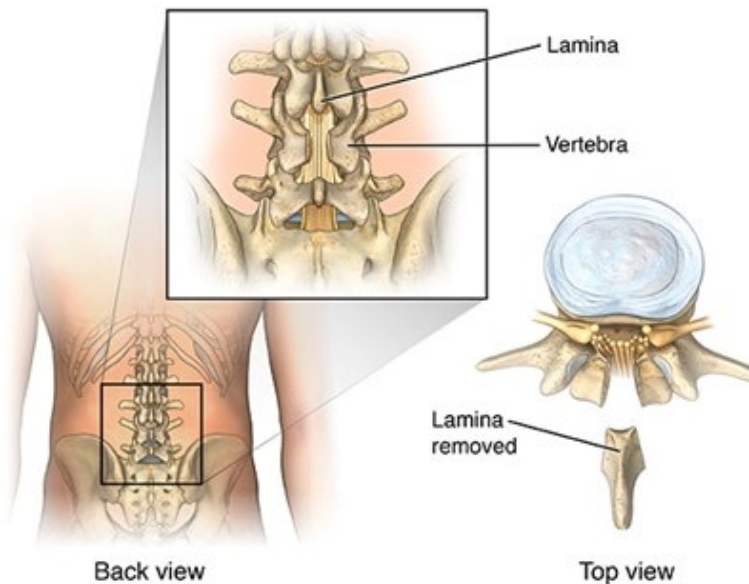
Through a research in medical databases, such as PubMed Central and Elsevier, a limited number of articles with the same casuistry were identified through related words such as: CSF, leak, occult dural tear, spinal surgery, blood patch.

RESULTS: The patient was diagnosed and treated accordingly and did not develop complications. The rehabilitation program was influenced by the appearance of a cerebrospinal fluid leak and the patient's return to the professional setting prior to the intervention was delayed. The multidisciplinary team ensured a complex care. The evolution of the case was favorable under balneo-physical-kinetic treatment in compliance with the discharge recommendations.

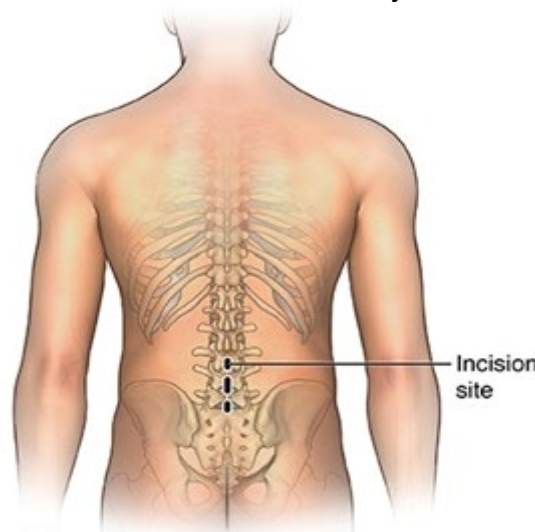
CONCLUSIONS: The management of this complication is controversial. It is necessary to describe a larger study sample in order to establish the optimal therapeutic behavior in the event of the appearance of a cerebrospinal fluid leak.

REFERENCES

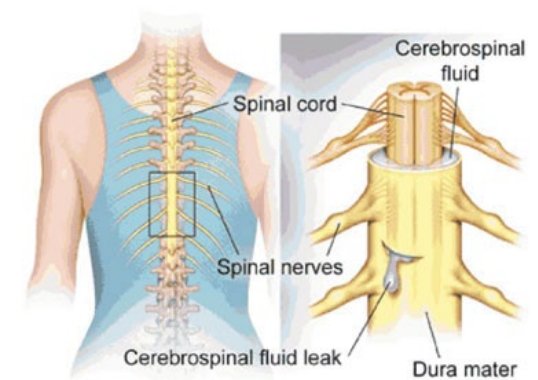
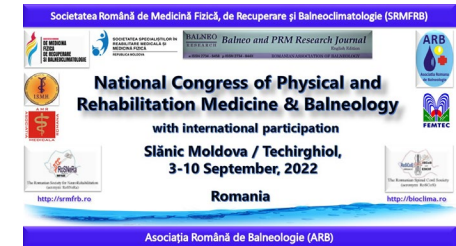1. <https://www.hopkinsmedicine.org/health/treatment-tests-and-therapies/laminectomy>
2. <https://www.pauljeffordsmd.com>



Picture 1- Laminectomy¹



Picture 2- Lumbar laminectomy incision¹



Picture 3- Cerebrospinal fluid leak²