Congresul Național de Medicină Fizică, de Recuperare și Balneoclimatologie
Covasna, 23 – 25 Aprilie 2026

MULTIDISCIPLINARY APPROACH INCLUDING DIAGNOSIS AND REHABILITATION STRATEGY IN A COMPLEX CASE OF PERIPHERAL FACIAL PARALYSIS (RECENT LEFT FACIAL PARALYSIS AND HISTORY OF RIGHT FACIAL PARALYSIS) IN A YOUNG POSTPARTUM PATIENT

Alexandru-Mihai Buturugă MD[1], Asist. Prof. Ioana Andone MD PhD[1,2], Monica Badea MD[1], Alexandra Georgiana Paruschi MD[1], Asist. Prof. Cristina Popescu MD[1] PhD[1,2], Asist. Prof. Aura Spînu MD[1] PhD[1,2], Cosmina Rață MD[1], Ciocoi Alina Iuliana MD[1], Prof. Gelu Onose MD PhD [1,2]

[1]*The Teaching Emergency Hospital "Bagdasar-Arseni" (TEHBA), Bucharest, Romania*
[2]*The University of Medicine and Pharmacy "Carol Davila" (UMPCD), Bucharest, Romania*

Disclosure statement

I have no actual or potential conflict of interest in relation to this program/presentation (number 10088).

Peripheral facial palsy

Peripheral facial palsy represents the impairment of the VII nerve (the facial nerve) due to lesions at the level of the facial nucleus or its axons along the entire length of the nerve, and it corresponds to a complete or incomplete paralysis of the hemiface on the affected side.

The most common form: Bell's palsy.
! Bell's palsy is preceded in about half of cases by pain in or around the ear. Depending on the location of the lesion, loss of taste or hyperacusis may also occur.*

*David Perkin, Douglas C. Miller, Russell Lane, Maneesh C. Patel, and Fred H. Hochberg, Atlas of Clinical Neurology, Third edition, 2010.

Anatomy of the facial nerve

- **Motor:** origin – the motor nucleus in the pons; exits the brainstem at the cerebellopontine angle; it enters the internal acoustic meatus toward the petrous part of the temporal bone, where it lies in the facial canal alongside cranial nerve VIII (At this level also arises the Stapedius nerve, which innervates the stapes); forms a relay at the geniculate ganglion; passes through the Fallopian canal in the petrous temporal bone; exits the skull via the stylomastoid foramen; traverses the parotid gland, becoming superficial, and distributes to the muscles of facial expression (muscles of the face, forehead and the platysma, as well as the region of the external ear)*, **

*Cursuri nervi cranieni, Prof. Dr. Gelu Onose

**Nica S., Davidescu I., Neurologie – Examinarea neurologica – Volumul I, Editura Universitara “Carol Davila”, Bucuresti, pg: 110-165, 2007

Anatomy of the facial nerve

- **Vegetative:** the preganglionic neurons are located in the superior salivatory nucleus, also in the pons (at this level receiving afferent fibers from the hypothalamus and from the trigeminal nucleus); the efferent fibers group into the intermediate nerve of Wrisberg (VII bis), which divides into the greater petrosal nerve (providing parasympathetic innervation to the lacrimal and nasal glands) and the chorda tympani nerve (which carries taste sensation and sends fibers to the submandibular and submaxillary salivary glands).*,**

*Cursuri nervi cranieni, Prof. Dr. Gelu Onose
**David Perkin, Douglas C. Miller, Russell Lane, Maneesh C. Patel, and Fred H. Hochberg, Atlas of Clinical Neurology, Third edition, 2010.

Anatomy of the facial nerve

- **Sensitive:** receptors – at the level of the concha, retroauricular region, external auditory canal, and tympanic membrane; first-order neurons – geniculate ganglion; fibers travel via the intermediate nerve of Wrisberg to the spinal tract nucleus of the trigeminal nerve (second-order neurons), then to the contralateral posteroventral thalamic nucleus (third-order neurons), with projection to the sensory cortex at the level of the postcentral gyrus.*

*Nica S., Davidescu I., Neurologie – Examinarea neurologica – Volumul I, Editura Universitara “Carol Davila”, Bucuresti, pg: 110-165, 2007

Anatomy of the facial nerve

- **Sensory:** receptor – taste cells at the level of the anterior two-thirds of the tongue and the soft and hard palate; carried by the chorda tympani nerve; first-order neurons – geniculate ganglion; second-order neurons – gustatory nucleus; third-order neurons – posteroventral thalamic nuclei, both contralateral and ipsilateral; cortical projection to the postcentral gyrus in the gustatory area, with extension into the insular cortex.*

*Nica S., Davidescu I., Neurologie – Examinarea neurologica – Volumul I, Editura Universitara “Carol Davila”, Bucuresti, pg: 110-165, 2007

Anatomy of the facial nerve

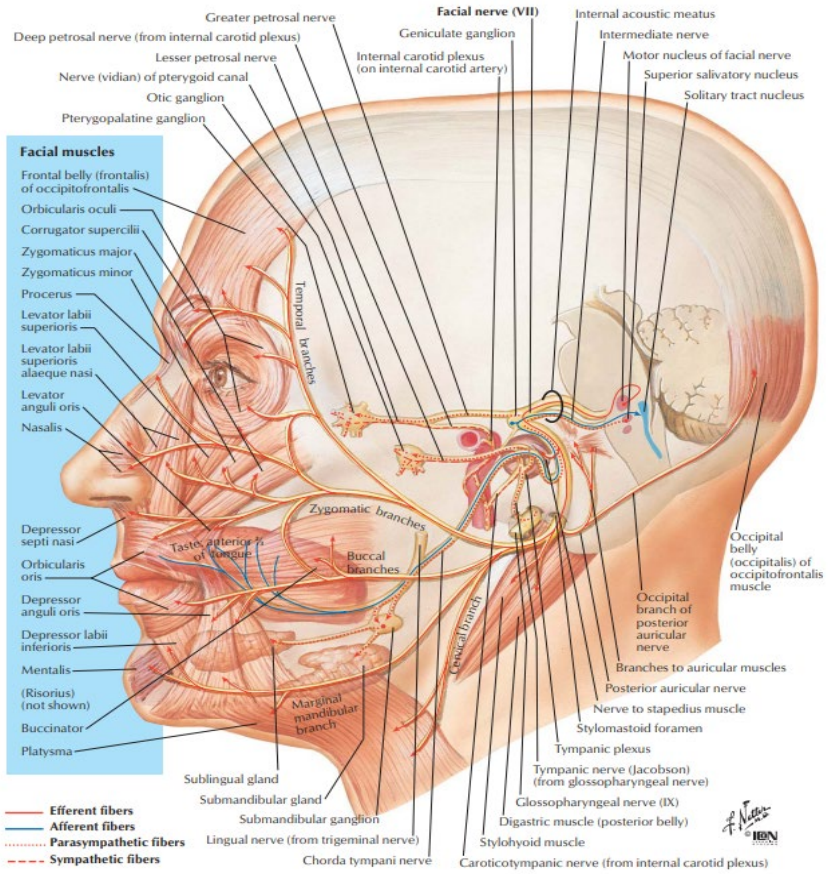

Facial Nerve, Atlas of Neuroanatomy and Neurophysiology, Netter et al., 2002

Examination of the facial nerve

- **Examination of facial motor function (bilateral):** ask the patient to raise their eyebrows, close their eyes, show their teeth, open their mouth, puff out their cheeks, and whistle. At the same time, assess the strength with which the patient performs these movements.
- **Examination of the corneal reflex.**
- **Examination of taste in the anterior two-thirds of the tongue.**
- **Examination of the appearance and sensitivity in the conchal, retroauricular, and external auditory canal regions.*,****

*Cursuri nervi cranieni, Prof. Dr. Gelu Onose

**Nica S., Davidescu I., Neurologie – Examinarea neurologica – Volumul I, Editura Universitara “Carol Davila”, Bucuresti, pg: 110-165, 2007

Metodology

- **Databases:** PubMed, Google Scholar.
- **Keywords:** facial nerve palsy, Bell's palsy, rehabilitation.
- **Time interval:** 2010-2026
- **Selection:** titles and abstracts were screened for relevance, followed by full-text evaluation of selected articles.

Literature review

In the study by Marc Hohman and Tessa Hadlock, entitled *"Etiology, diagnosis, and management of facial palsy: 2000 patients at a facial nerve center"*, the largest study of its kind in the past 25 years, conducted on a cohort of 1,989 patients, the most frequent cause was **Bell's palsy**, accounting for 38% (761 cases – 286 men and 496 women). Of these, **58 patients experienced recurrence**, and **82 cases were associated with pregnancy**, similar to the patient that will be presented further on.*
The second most common cause was **acoustic neuroma**, followed by head and neck cancers, iatrogenic injuries, viral causes (particularly Varicella zoster virus infection), trauma, Lyme disease, and autoimmune causes.*

Regarding peripheral facial palsy in the context of Lyme disease and autoimmune diseases—**these being among the most possible diagnoses at the time of our patient's presentation**—81 cases of paralysis were associated with Lyme disease, of which 7 were bilateral, while 32 were associated with autoimmune conditions, of which 13 were bilateral and 2 were recurrent.*

*Hohman MH, Hadlock TA. Etiology, diagnosis, and management of facial palsy: 2000 patients at a facial nerve center. Laryngoscope. 2014 Jul;124(7):E283-93.

Literature review

An article focused exclusively on the recurrence of **Bell's palsy**, conducted by S. Dong et al. in 2019, shows that the incidence of recurrence ranges between 0.8% and 19.4%, with an average of 6.5%, and is not influenced by the patient's sex. Furthermore, the study highlights that the likelihood of recurrence increases with the number of prior episodes, with probabilities of recurrence after one, two, and three recurrences being 0.19, 0.18, and 0.33, respectively.*

Regarding pharmacological treatment, prednisone and other oral corticosteroids reduce nerve swelling and might improve facial motions and expressions faster. These medications are most efficacious when started within 48 hours of the onset of symptoms. The suggested dose of prednisone is 60 mg orally once a day for five days which is then tapered to 10 mg per day. When taken with corticosteroids, antiviral drugs such as acyclovir (can be initiated at a dose of 400 mg orally five times a day and continued for 10 days in case of associated herpes infection) or valacyclovir (3g/day) are known to hasten the healing. This combination has a short treatment period and is cost-effective thus is very often recommended unless contraindicated. Ear pain can be relieved with the use of analgesics.**

*Dong SH, Jung AR, Jung J, Jung SY, Byun JY, Park MS, Kim SH, Yeo SG. Recurrent Bell's palsy. Clin Otolaryngol. 2019 May;44(3):305-312.
** Singh A, Deshmukh P. Bell's Palsy: A Review. Cureus. 2022 Oct 11;14(10):e30186.

Literature review

Rehabilitative treatment in **Bell's palsy** consists of physical therapies such as exercise, LASER therapy, electrotherapy, massage, and thermotherapy.

Regarding this type of treatment, the literature presents differing opinions. An article by L. Teixeira et al. questions the beneficial effects of physiotherapy and kinesiotherapy. The authors conclude that there is evidence from a single moderate-quality study that exercises are beneficial for patients with chronic facial palsy compared with controls, and from another low-quality study suggesting that facial exercises may help reduce synkinesis (a complication of Bell's palsy) and shorten recovery time.*

Only four trials (313 participants) evaluated the efficacy of electrical stimulation, three trials (199 participants) assessed exercises, and five studies (360 participants) investigated combinations of physical therapy compared with acupuncture, all of them with modest results.*

*Teixeira LJ, Valbuza JS, Prado GF. Physical therapy for Bell's palsy (idiopathic facial paralysis). Cochrane Database Syst Rev. 2011 Dec 7;2011(12):CD006283

Literature review

On the other hand, a recent review of Khan et al. 2022 provides new evidence from high-quality studies to support the use of facial exercise therapy in patients with facial palsy. The review identified nineteen new research studies, including eight randomised controlled trials, four quasi-experimental or pilot studies, and seven observational studies. These studies provide evidence on the effectiveness of facial exercise therapy in 839 patients with ages ranging from 12 to 80 years old. Moreover, these studies show that rehabilitation is more pronounced and faster when multiple therapies are used together, such as electrostimulation, laser therapy, and massage*

*Khan AJ, Szczepura A, Palmer S, Bark C, Neville C, Thomson D, Martin H, Nduka C. Physical therapy for facial nerve paralysis (Bell's palsy): An updated and extended systematic review of the evidence for facial exercise therapy. Clin Rehabil. 2022 Nov;36(11):1424-1449.

Literature review – clinical case preamble

- **Bell's palsy** is a common condition, with a higher prevalence in females.
- It presents a **broad spectrum of differential diagnoses**, including tumors (e.g., acoustic neuroma), infections (e.g., Lyme disease, varicella-zoster virus), trauma, and autoimmune disorders.
- It may be associated with various **pathological conditions or physiological states**, such as pregnancy.
- **Treatment** should include corticosteroids, antivirals, analgesics, as well as rehabilitation methods (kinesiotherapy and physiotherapy).
- While older studies reported **modest results** regarding the effectiveness of rehabilitation therapies, more recent research increasingly supports their **beneficial role in rehabilitation.**
- **Complete recovery** in most of the cases.

Case presentation

With the permission of the THEBA Ethics Committee (10088), this paper presents a case of a 32-year-old patient who was admitted on 2nd of February in our Neuromuscular Rehabilitation Department with:

- facial asimmetry
- left-sided otalgia
- left-sided peripheral facial palsy

Physiological personal history - pregnancy with a favorable course approximately one year ago, carried to term (38 weeks), without complications.

Case presentation

Pathological personal history - The patient is known with **right-sided peripheral facial palsy** (January 2023), treated in our clinic with corticosteroids, physiotherapy, and kinesiotherapy, with a very good outcome – complete remission of symptoms.

Additionally, on 31th of December 2025, she presented **left-sided otalgia**, followed by **left-sided peripheral facial palsy**, which led her to seek emergency neurological evaluation. Corticosteroid and vitamin therapy were initiated, and she subsequently underwent an otorhinolaryngology evaluation along with a series of recommended laboratory investigations. Due to a slow recovery, she was admitted to our clinic on 2nd of February 2026.

Case presentation

NMAK examination

The patient was conscious, cooperative, and oriented in time and space. No signs of meningeal irritation are present. There was **left-sided peripheral facial palsy**, with left lagophthalmos (Bell's sign positive), flattening of the left nasolabial fold, and drooping of the left oral commissure, as well as left-sided otalgia. Synkinesis were present. There was no taste or salivary disturbances. The rest of the cranial nerve examination was normal. There was no facial sensory disturbances, no motor deficits, and paresis tests were negative. Romberg test was negative, with no balance or sphincter disturbances.

The general clinical examination showed no abnormalities.

Case presentation

Case presentation

Case presentation

To assess the severity of peripheral facial palsy, we used the **House–Brackmann scale**. At the time of presentation, the patient was classified as **grade V**. The House-Brackmann scale is a standardized and free medical instrument.

Grade	Description	Eye Closure	Forehead Movement	Mouth Movement	Synkinesis
I	Normal facial function in all areas.	Complete	Normal	Symmetrical	None
II	Slight weakness; normal tone & symmetry at rest.	Complete, slight effort	Normal	Slight asymmetry	Mild
III	Moderate dysfunction; no noticeable weakness at rest.	Complete, with effort	Slightly reduced	Asymmetry present	Noticeable
IV	Severe dysfunction; obvious facial weakness.	Incomplete	No movement	Asymmetry with effort	Present
V	Severe dysfunction; minimal facial motion.	Incomplete	No movement	Very asymmetrical	Present
VI	Total facial paralysis; no motion.	None	No movement	No movement	None

House-Brackmann assessment (https://facialparalysisinstitute.com/conditions/house-brackmann-grading-system/)

Case presentation

Paraclinical assessment

Routine laboratory tests performed at admission did not reveal any significant abnormalities. Additionally, taking into account recurrence of the facial palsy, for an accurate diagnosis, viral and tumoral markers were assessed to identify these etiologies (results within normal limits).

Test	Rezultat	UM	Interval de referinta
Ac Anti-CMV IgM Ser, metoda CMIA, Alinity Abbott	Nonreactiv (0.42 index)		Nonreactiv: index < 0.85 Echivoc: index 0.85 - 1.00 Reactiv: index >=1.00
Ac Anti-CMV IgG Ser, metoda CMIA, Alinity Abbott	Reactiv (210.40 AU/mL)		Nonreactiv: < 6 AU/mL Reactiv: >= 6 AU/mL
Ac Anti-Herpes 1 IgM ** Ser, metoda ELISA, ALEGRIA	11.6	U/ml	Negativ <20 U/ml Echivoc 20-25 U/ml Pozitiv >25 U/ml
Ac Anti-Herpes 1 IgG ** Ser, metoda ELISA, ALEGRIA	41.3	Index	Negativ: < 0.9 Index Echivoc: 0.9 - 1.1 Index Pozitiv: > 1.1 Index Schimbare de metoda iunie 2013
Ac Anti-Herpes 2 IgM ** Ser, metoda ELISA, ALEGRIA	14.2	U/ml	Negativ <20 U/ml Echivoc 20-25 U/ml Pozitiv >25 U/ml
Ac Anti-Herpes 2 IgG ** Ser, metoda CLIA, Liaison - Diasorin	< 0.5	Index	Negativ: < 0.9 Index Echivoc: 0.9 - 1.1 Index Pozitiv: > 1.1 Index Schimbare de metoda iunie 2013
Ac Anti-Epstein Barr VCA IgM ** Ser, metoda CLIA, Liaison - Diasorin	< 10	U/mL	Negativ: < 20 U/mL Echivoc: 20 - 40 U/mL Pozitiv: > 40 U/mL (Schimbare de metoda: 24.09.2013)
Ac Anti-Epstein Barr VCA IgG ** Ser, metoda CLIA, Liaison - Diasorin	71.4	U/mL	Negativ: <20.0 U/mL Pozitiv: >=20.0 U/mL
Virus varicelo-zosterian Ac IgG ** Ser, metoda CLIA, Liaison - Diasorin	207.9	mUI/mL	Negativ: < 150 mUI/mL Pozitiv: >= 150 mUI/mL
Virus varicelo-zosterian Ac IgM ** Ser, metoda CLIA, Liaison - Diasorin	0.362	Index	Negativ: <1.0 Index Pozitiv: >= 1.0 Index

* SPR CA 15 - 3 (Antigen carbohidrat) Ser / ECLIA - Electrochemiluminiscenta	18.4	U/mL	< 28.5
SPR HIV 1 si 2 - anticorpi si antigen Ser / electrochemiluminiscenta (HIV combi)	negativ		negativ
* SPR CA 125 (Antigen tumoral) Ser / electrochemiluminiscenta (ECLIA)	22	U/mL	≤ 35
* SPR CA 19 - 9 (Antigen carbohidrat) Ser / electrochemiluminiscenta (ECLIA)	2.3	U/mL	< 27
* SPR CEA (Antigen carcinoembrionic) Ser / Electrochemiluminiscenta	0.7	ng/mL	Nefumatori:<3 Fumatori:<5

Case presentation

Paraclinical assessment

Borrelia - Anticorpi IgG, IgM (Blot)
Ser / microblot array

p83	negativ	negativ
p58	negativ	negativ
p41 Ba	negativ	negativ
p41 Bs	negativ	negativ
p39	negativ	negativ
OspB	negativ	negativ
OspA Ba	negativ	negativ
OspA Bg	negativ	negativ
OspA Bs	negativ	negativ
OspC Ba	negativ	negativ
OspC Bg	negativ	negativ
OspC Bs	negativ	negativ
OspC Bsp	negativ	negativ
NapA	negativ	negativ
OspE	negativ	negativ
p17	negativ	negativ
Anaplasma IgM	NEGATIV	NEGATIV
OmpA	negativ	negativ
p44	negativ	negativ
Asp62	negativ	negativ

Borrelia - Anticorpi IgG, IgM (Blot)
Ser / microblot array

Borrelia IgG	ECHIVOC	NEGATIV
VlsE Ba	negativ	negativ
VlsE Bg	pozitiv	negativ
VlsE Bs	negativ	negativ
p83	negativ	negativ
p58	negativ	negativ
p41 Ba	negativ	negativ
p41 Bs	negativ	negativ
p39	negativ	negativ
OspB	negativ	negativ
OspA Ba	negativ	negativ
OspA Bg	negativ	negativ
OspA Bs	negativ	negativ
OspC Ba	negativ	negativ
OspC Bg	negativ	negativ
OspC Bs	negativ	negativ
OspC Bsp	negativ	negativ
NapA	negativ	negativ
OspE	negativ	negativ
p17	negativ	negativ
Anaplasma IgG	NEGATIV	NEGATIV
OmpA	negativ	negativ
p44	negativ	negativ
Asp62	negativ	negativ
Borrelia IgM	NEGATIV	NEGATIV
VlsE Ba	negativ	negativ
VlsE Bg	negativ	negativ
VlsE Bs	negativ	negativ

Case presentation

Interdisciplinary consults

The patient was evaluated from several specialties point of view:

- **Neurology 31st of December 2025:** acute left-sided peripheral facial palsy. Recommendations: brain MRI with arterial and venous MR angiography sequences with contrast; routine laboratory tests; antibodies for HSV 1 and 2, anti-*Borrelia*, anti-CMV, anti-VZV, anti-EBV, anti-HIV, and angiotensin-converting enzyme. Treatment: prednisone 5 mg – 12 tablets/day for 5 days, followed by a taper of 2 tablets/day over the next 5 days; Tiolin Complex; and discontinuation of breastfeeding during treatment (which was not carried out).
- **Neurology 21st of January 2026:** left-sided peripheral facial palsy, with inability to achieve complete eyelid closure of the left eye. The patient denies facial hypoesthesia. No motor deficits are present, and neurological tests are negative. Recommendations: prednisone 1 mg/kg (16 tablets/day) for 10 days, followed by tapering by 1 tablet/day; Tiolin; anti-HIV antibodies; anti-*Borrelia* antibodies; brain MRI with MR angiography including venous suppression; discontinuation of breastfeeding during treatment.

Case presentation

Paraclinical assessment

Cranio-cerebral MRI performed both native and post-contrast, with MR angiography sequences, was within normal limits, showing no pathological intra- or extra-axial contrast enhancement in the infra- and supratentorial compartments.

REZULTAT:

Examinarea IRM craniocerebrala efectuata nativ si postcontrast + secvente angioRM evidentiaza:
-fara anomalii de semnal intracerebrale, infra sau supratentoriale;
-fara leziuni acute vizibile intracerebral in ponderatie de difuzie;
-fara stigmate de sangerare pe secventa SWi supra- sau infratentorial;
-spatiile lichidiene pericerebrale si cisternele bazale sunt normale;
-sistem ventricular de dimensiuni normale, simetric;
-structurile liniei mediane in pozitie normala;
-axele vasculare ale poligonului Willis apar cu morfologie si semnal in limite normale;
-sinsuri venoase cu morfologie si semnal in limite normale;
-conducte auditive interne, unghiuri ponto-cerebeloase simetrice, cu morfologie normala;
-aspect de bucla vasculara in sistemul vertebro-bazilar ce ocupa cisterna pontocerebeloasa bilateral cu posibil conflict vasculo-nervos la acest nivel;
-sinusurile paranazale si celulele mastoidiene sunt normale;
-discreta deviatie de sept nazal catre dreapta;
-hipertrofia cornetelor nazale bilateral;
-hiperostoza corticala interna frontal bilateral.

Aspect IRM cerebral in limite normale.
Fara prize patologice de contrast intra/extranevraxial in etajul infra/supratentorial.

Case presentation

Interdisciplinary consults

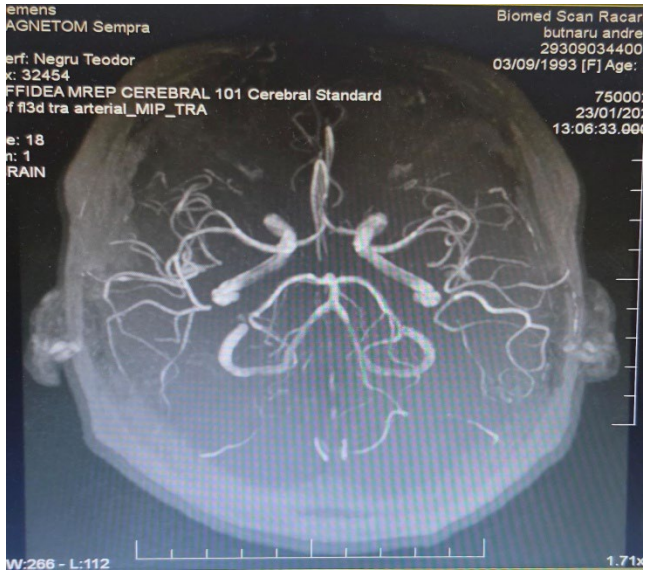

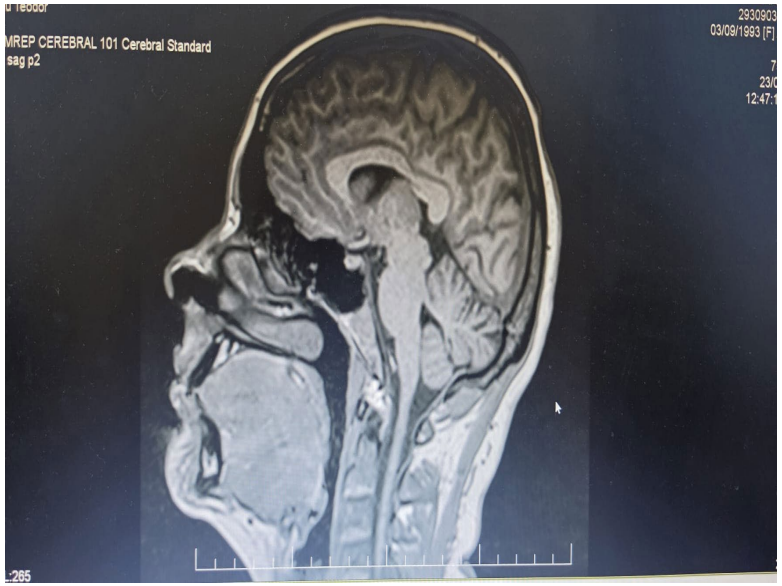

Case presentation

Interdisciplinary consults

The patient was evaluated by several specialties doctors:

- **Otorhinolaryngology 15th of January 2026:** left-sided peripheral facial palsy, normal audiogram, Tympanometry: the stapedial reflex is present in the right ear and absent in the left ear. Recommendations: continuation of the treatment prescribed by neurology.
- **Otorhinolaryngology 23 of January 2026:** left-sided peripheral facial palsy without any other findings. Recommendations: Vitamine C intravenous 400mL/day, 5 days, Neuromultivit 3 tablets/day, 5 days.

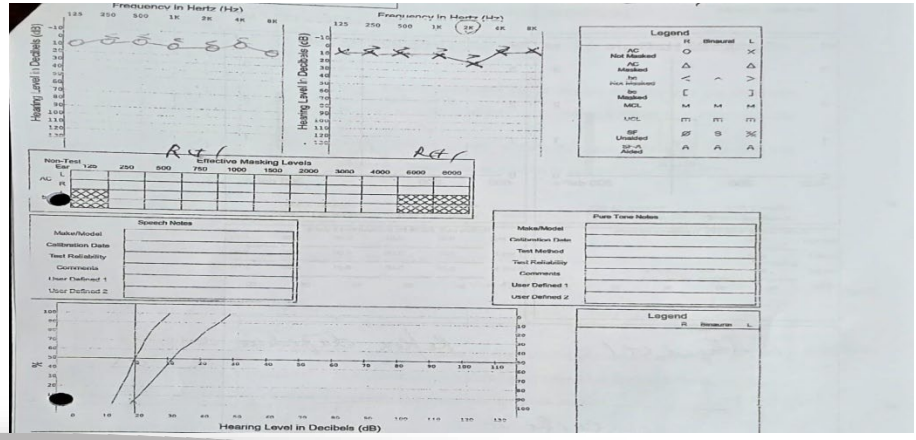

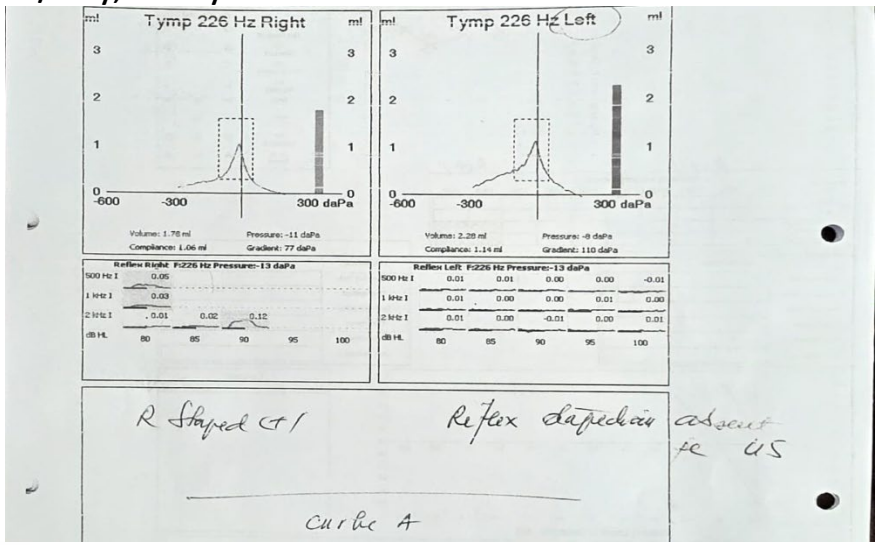

Case presentation

Interdisciplinary consults

The patient was evaluated by several specialties doctors:

- **Infectious Diseases 21st of March:** afebrile, with no overlying skin lesions and no relevant epidemiological context. The patient denies a history of tick exposure or travel to high-risk areas. Recommendations: initiation of corticosteroid therapy, reduction of salt intake to less than 2 g/day, and Valacyclovir 3 g/day.

Case presentation

Interdisciplinary consults

The patient was evaluated by several specialties doctors:

- **Hematology:** clinical and laboratory examination were normal, with no hematological disorders. Following the hematologist's recommendation, a molecular analysis of thrombophilia risk was performed, identifying several mutations and alleles (Factor V H1299R, MTHFR A1298C mutations, and PAI-1 4G, HPA1 b, ACE D alleles), which may confer a low risk of thrombosis and myocardial infarction, but are not related to the peripheral facial palsy in this case.Recommendations: caution and special precautions when using oral anticoagulants and antiplatelet agents, as well as administration of Vessel Due, folic acid, and vitamin D.

Method:

DNA was extracted from the peripheral blood sample. Twelve gene mutations and alleles, that have been associated with genetically determined risk of thrombophilia and/or Cardiovascular Diseases, were screened using multiplex PCR with biotinyl primers followed by a reverse hybridization assay (CVD StripAssay, IVD, ViennaLab). The mutations screened using the ab mentioned technique are: Factor V Leiden (1691G>A; R506Q), Factor V H1299R (R2), Prothrombin (PTH; Factor II) 20210G 5,10-Methylenetetrahydrofolate Reductase (MTHFR) C677T and A1298C, Factor XIII (FXIII) V34L, Plasminogen Activator Inhib 1 (PAI-1, Serpin E1) 4G/5G, Beta-Fibrinogen (FGB) -455G>A, Angiotensin-Converting Enzyme (ACE) 287 bp insertion/dele (I/D), Human Platelet Antigen 1 (HPA1a/b; Gp IIIa; integrin beta 3 L33P), Apolipoprotein B (Apo B) R3500Q, Apolipoprotei (Apo E) E2/E3/E4.

Result:

FV: Leiden normal & R2 heterozygous
PTH: G20210A normal
FXIII: V34L normal
βFG: -455 G>A normal
PAI-1: 4G/5G
HPA1: a/b
MTHFR: C677T normal & A1298C heterozygous
ACE: I/D
ApoB: R3500Q normal
ApoE: E3/E3

Conclusion:

The Factor V H1299R (R2), MTHFR A1298C mutations and the PAI-1 4G, HPA1 b, ACE D alleles were detecte heterozygosity in the analyzed sample.

Case presentation

Differential diagnosis

Infectious causes:
- Lyme disease
- Ramsay-Hunt syndrome
- Herpes Simplex infection
- CMV infection
- Epstein-Barr infection
- Otitis media
- Parotitis

Tumoral causes:
- Acoustic neuroma
- Parotid tumors
- Head and neck cancers
- Intracranial metastases

Neurological causes:
- Stroke
- Multiple sclerosis
- Millard-Gubler syndrome

Traumatic causes:
- Cranial trauma
- Temporal bone fracture
- Iatrogenic injuries (ENT surgery, parotid surgery, neurosurgery)

Autoimmune / inflammatory causes:
- Sarcoidosis
- Guillain-Barré syndrome
- Vasculitis – lupus (systemic lupus erythematosus)

Metabolic and systemic causes:
- Diabetes mellitus
- Hypertension

Case presentation

Diagnosis

Bell's palsy is a diagnosis of exclusion, requiring the elimination of infectious, neoplasic, neurological, traumatic, autoimmune, and metabolic causes.

Case presentation

Treatment

Hygienic-dietary: ocular hygiene is essential because blinking may be difficult; thorough local care is recommended, possibly including eye drops and an eye patch during sleep. Important: avoid cold exposure! A low-sodium diet during corticosteroid treatment.

Pharmacological: prednisone 1 mg/kg body weight (16 tablets/day) for 10 days, followed by tapering by one tablet per day (very important: discontinue breastfeeding during corticosteroid therapy.); valacyclovir 500 mg, 3 g/day (2 tablets three times daily) for 5 days; vitamin C intravenously 400 mL/day for 5 days; Neuromultivit 3 tablets/day for 5 days; and Tiolin 1 tablet twice daily for 5 days starting from discharge.

Case presentation

Treatment

Physiotherapy: general objectives - reduction of inflammation and pain, correction of facial asymmetry, socio-professional reintegration.

- Electrostimulation of denervated muscles can be performed using low-frequency exponential currents (10–200 Hz). It is useful for restoring muscle tone.
- Galvanic current – iontophoresis with 1% potassium iodine (KI): negative electrode 2×2 cm^2, covering soaked in 1% KI (with an effect of enhancing nerve conduction) placed preauricularly; positive electrode 5×5 cm^2 with a thick hydrophilic layer soaked in distilled water, placed retroauricularly for 20 minutes, intensity at vibration threshold.
- LASER – applied at the level of the affected temporomandibular joint, Commissural and supraocular: 4 points, 3 J/cm^2, frequency 5 Hz, probe area 1 cm^2, power 60 mW. It has a biostimulating effect, modulating local and systemic cellular metabolic processes involved in regeneration.

Case presentation

Treatment

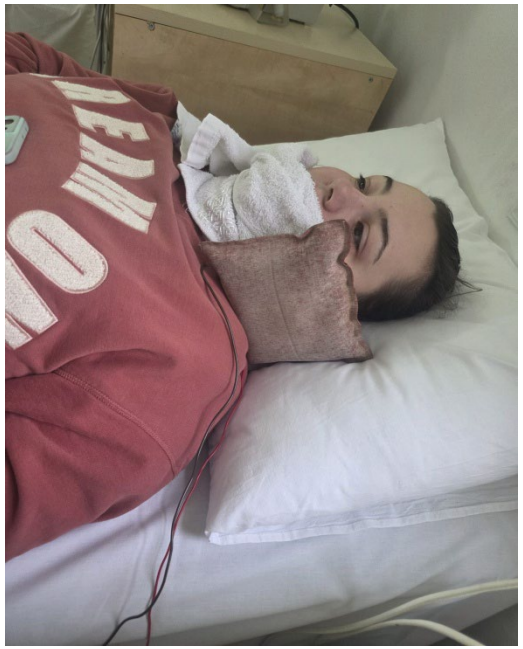

Case presentation

Treatment

Massage – increases basal metabolism and local circulation, reduces muscle fatigue, and has a trophic and toning effect on hypotonic muscles; it also serves as a warm-up before physiotherapy sessions.
However, a gentle massage is recommended, with the main aim of increasing blood circulation in the affected area. It should be performed over the entire face, symmetrically, in sessions of approximately 10 minutes.

Case presentation

Treatment

Exercise therapy: objectives – increasing muscle strength at the level of the facial mimic muscles and improving facial motor control.

- exercises for increasing muscle strength at the level of the facial muscles in front of the mirror;
- the exercises are performed slowly, in order to recruit as many motor units as possible;
- when working with the muscles of the upper part of the face, the muscles of the lower part will not be activated and vice versa;

The actual exercises include:

- chewing gum to tone the masseter muscles;
- inflation of the nostrils;
- inward rolling of the upper lip and protrusion of the lower lip;
- bringing the lips together with pressure;
- lip pursing as for whistling;
- smile without showing teeth;
- smile showing teeth;
- slow closing of the eye is attempted, without lowering the eyebrow;
- the eyebrow is raised and maintained for 10–15 seconds;
- the forehead is wrinkled;
- closing of the eyes is attempted alternately;
- the patient is asked to articulate: a, e, i, o, u;

Case presentation

Treatment

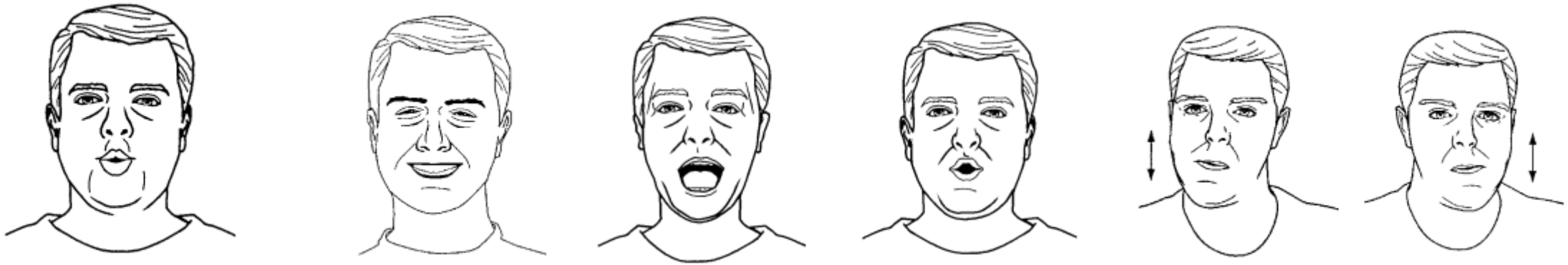

Pucker lips | Smile | "O" Exercise | Tongue-in-Cheek Push

Facial Strengthening Exercises, Department of Rehabilitation Services The Ohio State University Medical Center

Case presentation

Results

After 3 weeks of complex and intensive treatment, consisting of corticosteroid therapy, antivirals, vitamin treatment, physiotherapy, and therapeutic exercise, the patient shows a significant (but not complete) improvement of symptoms, both subjectively and objectively.

At the time of admission, the patient was at grade V on the House–Brackmann scale, and at discharge she was at grade III-IV. The patient reported feeling better, stating that the symptoms were no longer as pronounced, and objectively a moderate-to-severe dysfunction was observed. Eye closure could be achieved completely, but with significant effort; forehead movement was moderately reduced; and synkinesis was still present but more difficult to observe. The most evident aspect is the appearance at rest, in which the asymmetry, although still present, is no longer as pronounced.

Case presentation

Results



Case presentation

Evolution

After 2 months from discharge, the patient is readmitted to our clinic, with symptoms remaining stationary since the time of discharge. It should be noted that during these 2 months the patient has performed physical exercises, but inconsistently. This fact highlights the importance of treatment in this condition, recovery being much faster under appropriate physiotherapeutic-kinetic and pharmacological treatment, and almost nonexistent in its absence.

Case presentation

Evolution

Case presentation

Prognostic

Ad vitam prognosis – excellent, Bell's palsy not being life-threatening condition, motivated patient with good compliance to treatment.

Ad functionem prognosis – favorable, the patient begins to recover the deficit.

Ad laborum prognosis – favorable, with adequate eye protection, the patient working on the computer.

However, the risk of recurrence is higher when there have been multiple episodes of Bell's palsy.*

*Dong SH, Jung AR, Jung J, Jung SY, Byun JY, Park MS, Kim SH, Yeo SG. Recurrent Bell's palsy. Clin Otolaryngol. 2019 May;44(3):305-312.

Case presentation

Discussions

Rapid intervention is essential in this condition, as recovery is faster the earlier treatment is initiated.

A notable aspect is the occurrence of a new episode of peripheral facial palsy, with contralateral involvement compared to the initial episode, at an interval of approximately 3 years.

Unilateral facial nerve palsies are primarily expected during pregnancy or in the immediate post-partum period and the prognosis of Bell's palsy in pregnancy is not that good (The pathophysiological mechanism is represented by the increased inflammatory substrate during pregnancy, which appears to cause changes at the level of the *vasa nervorum* and, consequently, ischemia of the facial nerve.). The recovery rates in cases of complete paralysis of facial muscles have been lesser than those of general population. Bell's palsy occurs most commonly in two age groups, mainly less than 40 years of age and above 60 years of age. The reason why it occurs at this younger age is suspected to be due to its increased occurrence during pregnancy.*

*David Perkin, Douglas C. Miller, Russell Lane, Maneesh C. Patel, and Fred H. Hochberg, Atlas of Clinical Neurology, Third edition, 2010.

Case presentation

Particularities of the case

The particularity of the case is represented by the contralateral recurrence of peripheral facial palsy in a young individual, at a relatively long time interval postpartum compared to the literature.

Bibliography

1. Cursuri nervi cranieni, Prof. Dr. Gelu Onose.
2. David Perkin, Douglas C. Miller, Russell Lane, Maneesh C. Patel, and Fred H. Hochberg, Atlas of Clinical Neurology, Third edition, 2010.
3. Dong SH, Jung AR, Jung J, Jung SY, Byun JY, Park MS, Kim SH, Yeo SG. Recurrent Bell's palsy. Clin Otolaryngol. 2019 May;44(3):305-312.
4. Hohman MH, Hadlock TA. Etiology, diagnosis, and management of facial palsy: 2000 patients at a facial nerve center. Laryngoscope. 2014 Jul;124(7):E283-93.
5. Khan AJ, Szczepura A, Palmer S, Bark C, Neville C, Thomson D, Martin H, Nduka C. Physical therapy for facial nerve paralysis (Bell's palsy): An updated and extended systematic review of the evidence for facial exercise therapy. Clin Rehabil. 2022 Nov;36(11):1424-1449.

Bibliography

6. Nica S., Davidescu I., Neurologie – Examinarea neurologica – Volumul I, Editura Universitara “Carol Davila”, Bucuresti, pg: 110-165, 2007
7. Singh A, Deshmukh P. Bell's Palsy: A Review. Cureus. 2022 Oct 11;14(10):e30186.
8. Teixeira LJ, Valbuza JS, Prado GF. Physical therapy for Bell's palsy (idiopathic facial paralysis). Cochrane Database Syst Rev. 2011 Dec 7;2011(12):CD006283.
9. Facial Strengthening Exercises, Department of Rehabilitation Services The Ohio State University Medical Center

Va multumesc!